

# *MR Elastography of the Liver*

Stacey Speer, MD

Cross-Sectional Fellow

Western University

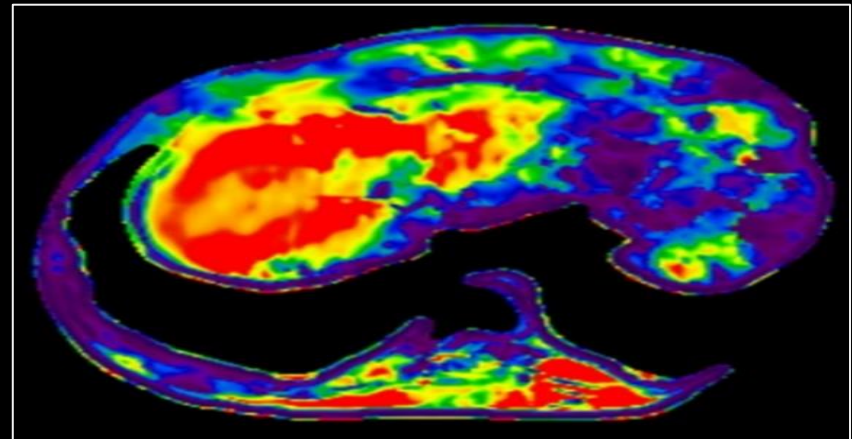
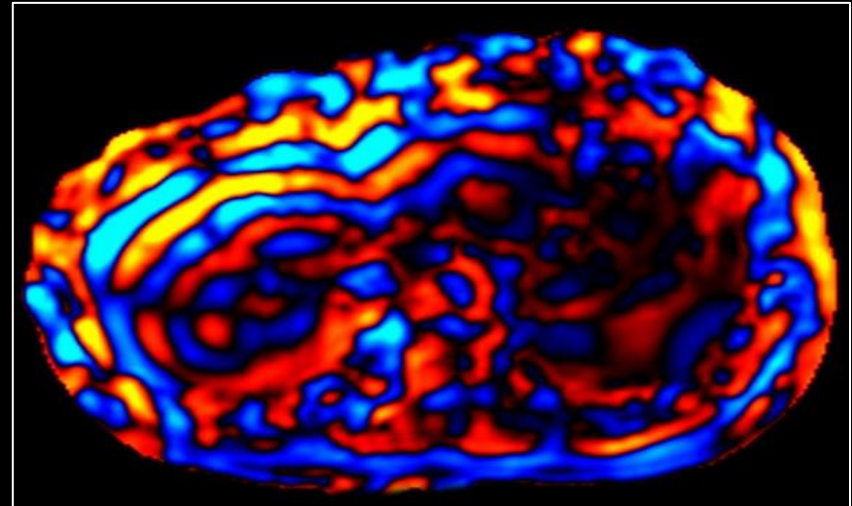
St. Joseph's Health Care London

Zahra Kassam, MD FRCPC

Assistant Professor of Medical Imaging

Western University

St. Joseph's Health Care London

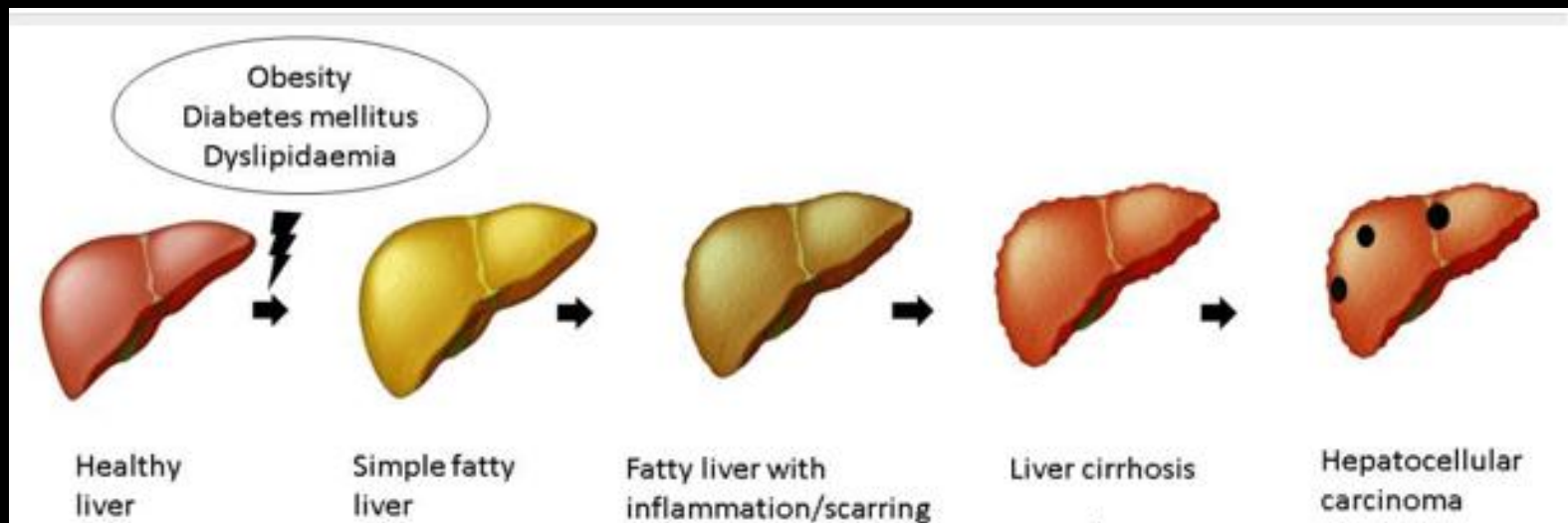


# Objectives

- Elastography
  - Background
  - Chronic liver disease
  - Principles and techniques of MRE
  - Mechanical properties of tissue
- Clinical utility of MRE
- Quality Assurance Cases

# Chronic Liver Disease

- Final common pathway of chronic liver disease begins with inflammation and tissue destruction, followed by attempts at regeneration and healing.
- Repeated episodes of tissue injury and healing lead to fibrosis and eventual cirrhosis.



# Causes of Chronic Liver Disease

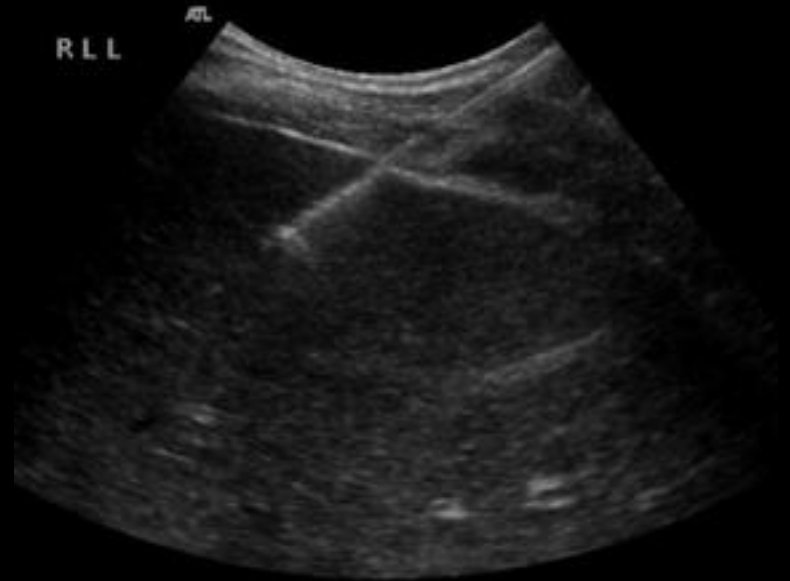
- Viral infection - Hepatitis
- Alcohol abuse
- Nonalcoholic steatohepatitis (NASH)
- Biliary disease - PSC
- Autoimmune disease
- Metabolic – Hemochromatosis
- Medications - Methotrexate

# Importance of Chronic Liver Disease, Fibrosis, Cirrhosis

- A leading cause of death world-wide.
- Increasing prevalence of conditions that cause hepatic fibrosis.
  - Hepatitis C - 160 M people globally.
  - Hepatitis B – 240 M people globally.
  - NAFLD – 27-34% of the US population.
  - Hepatocellular carcinoma is the fastest growing malignancy in North America.
- Fibrosis can be reversed, if diagnosed early and treated.

# Liver Biopsy

- Current reference standard for the diagnosis of hepatic fibrosis.
- Core sampling of 5 – 11 tracts with each sample measuring 2 cm in length for reliable diagnosis.
- Risks: hemorrhage (1.7%), death (0.01-1%).
- Sampling error due to heterogenous distribution.
- Subjective pathology grading – 20% inter-observer error rate in disease staging.



Ultrasound Guided Liver Biopsy

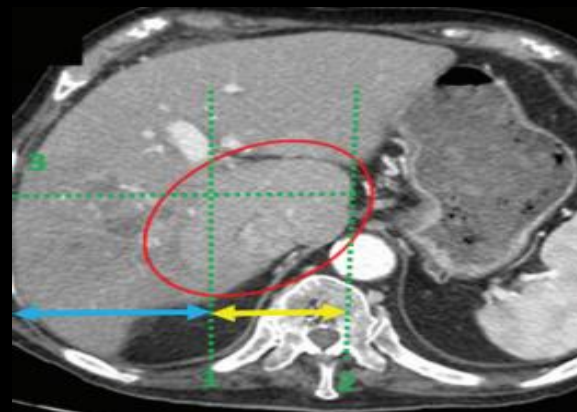
# Imaging of Chronic Liver Disease

## Imaging Features

1. Anatomic distortion
2. Changes in parenchymal attenuation or signal intensity
3. Alterations in dynamic contrast enhancement
4. Assessment of complications:
  - Hepatocellular carcinoma
  - Portal hypertension
    - dilated portal vein ( $>1.3$  cm)
    - cavernous transformation of the umbilical vein
    - splenomegaly
    - ascites
    - varices

## Anatomic Signs of Cirrhosis

- Surface nodularity
- Segmental hypertrophy or atrophy
- Enlarged periportal hilar space
- Enlarged gallbladder fossa
- Widened fissure
- Posterior hepatic notch
- Caudate lobe to right lobe ratio



# MRE Clinical Indications

- Detection and staging fibrosis in chronic liver disease.
- Follow up of previously diagnosed fibrosis.
- Assessment of treatment response in patients with hepatic fibrosis.



# Elastography – Virtual Palpation

- Indirect measure of tissue “stiffness”, acquired by measuring the propagation velocity of mechanical waves within tissues.
- Shear waves travel faster through solid media...
  - Inflamed, fibrotic or cirrhotic liver
- And slower through soft media
  - Normal or fatty liver



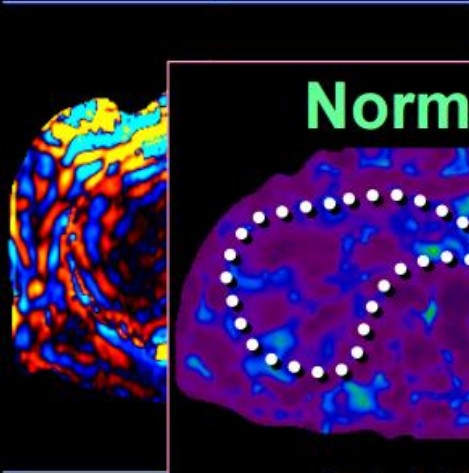
# Stage of Fibrosis

**Table 3: Correlation between MR Elastographic Stiffness and the Stage of Fibrosis**

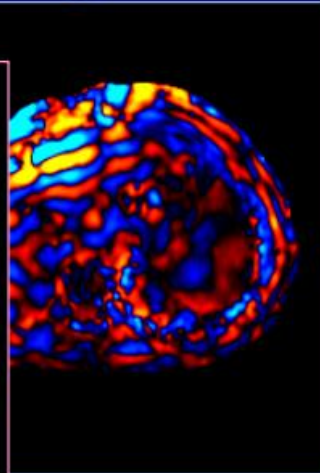
MR Elastographic Stiffness (kPa)	Stage of Fibrosis
Less than 2.5	Normal
2.5–2.9	Normal or chronic inflammation
2.9–3.5	Stage 1–2
3.5–4.0	Stage 2–3
4.0–5.0	Stage 3–4
More than 5.0	Stage 4

# Liver Fibrosis

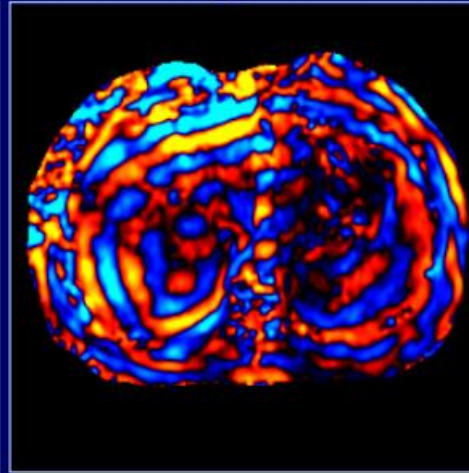
Biopsy:  
Stage F1



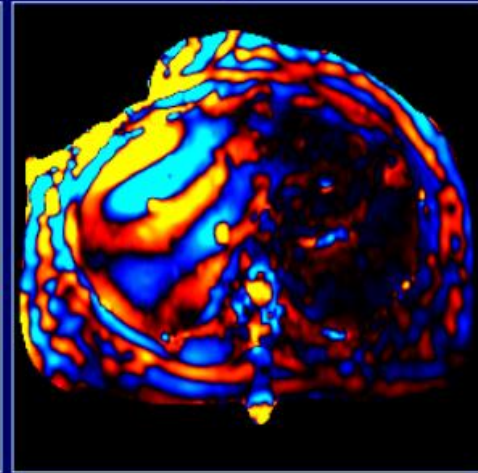
Biopsy:  
Stage F2



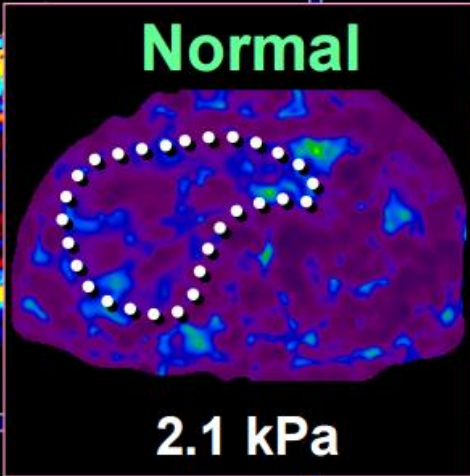
Biopsy:  
Stage F3



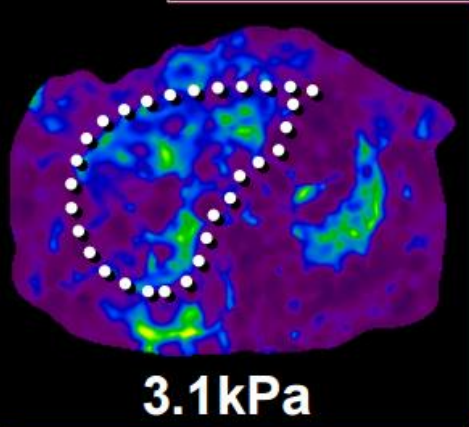
Biopsy:  
Stage F4



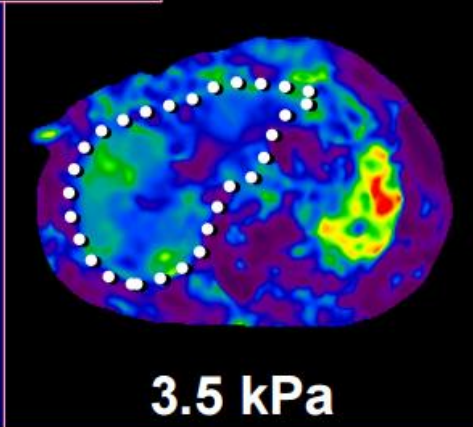
Normal



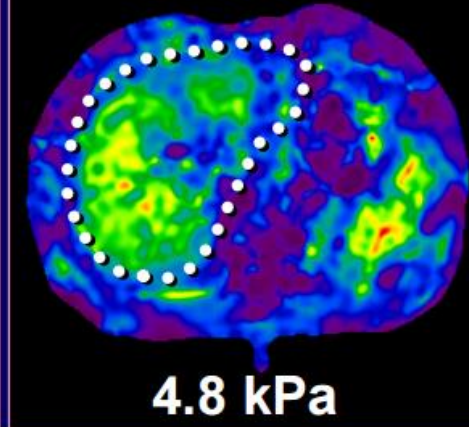
2.1 kPa



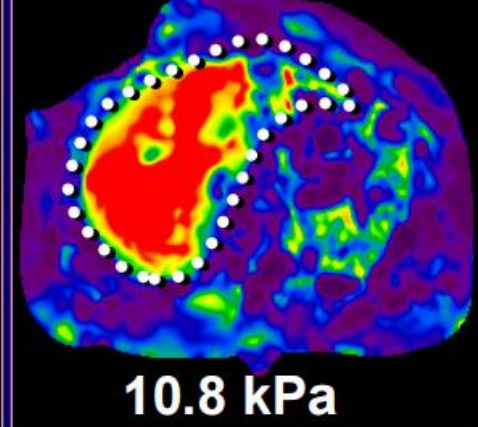
3.1 kPa



3.5 kPa



4.8 kPa

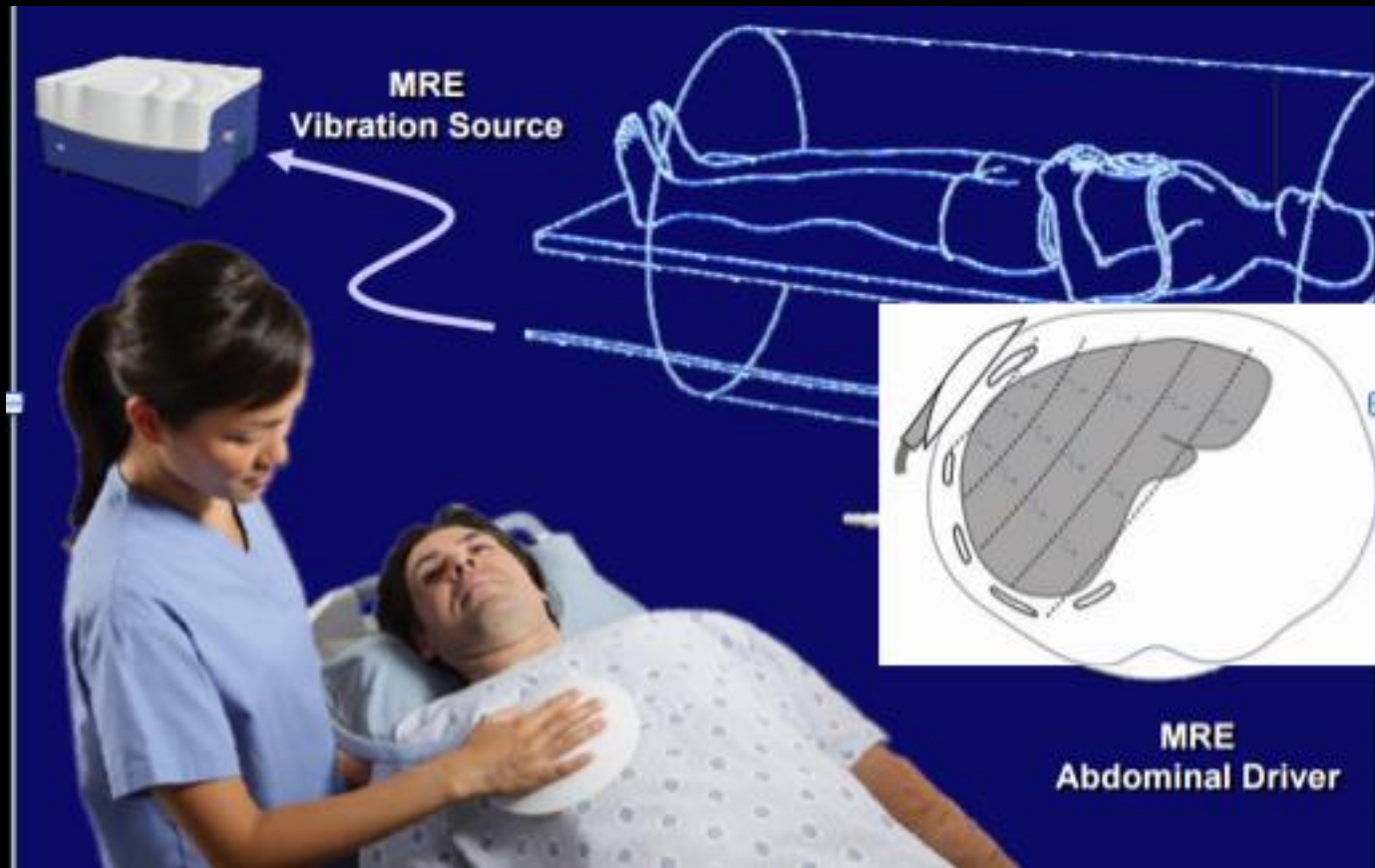


10.8 kPa



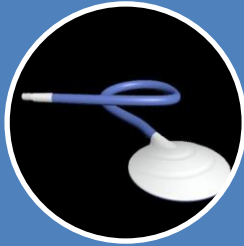
Slide Credit: R. Ehman, MD

# MR Acoustic Wave Generator






# MRE Methodology

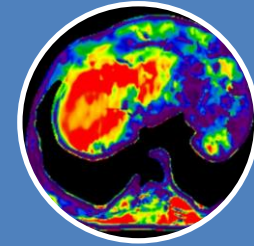


**Acoustic driver** - Applies stress/source of motion that deforms tissue.



**MRE Sequence** - Image tissue response to the stress

- Tissue displacement
- Velocity



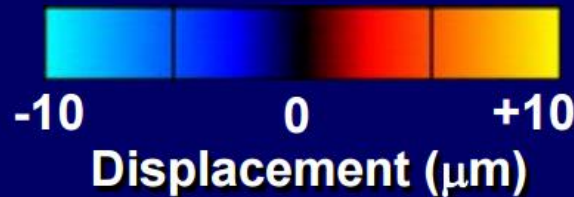
**Inversion** - generates elastogram (image)

- Shear Stiffness (kPa)

2.5cm



**Conventional  
MR Image**



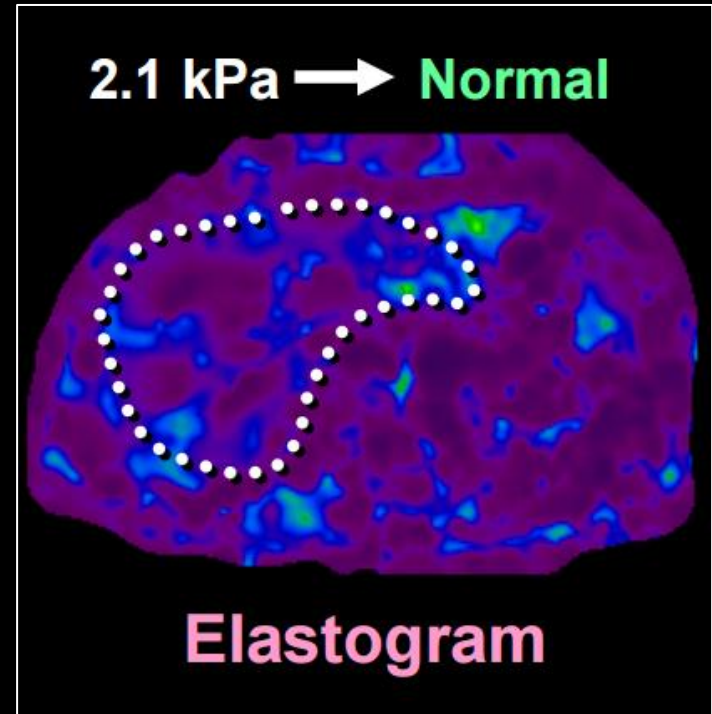
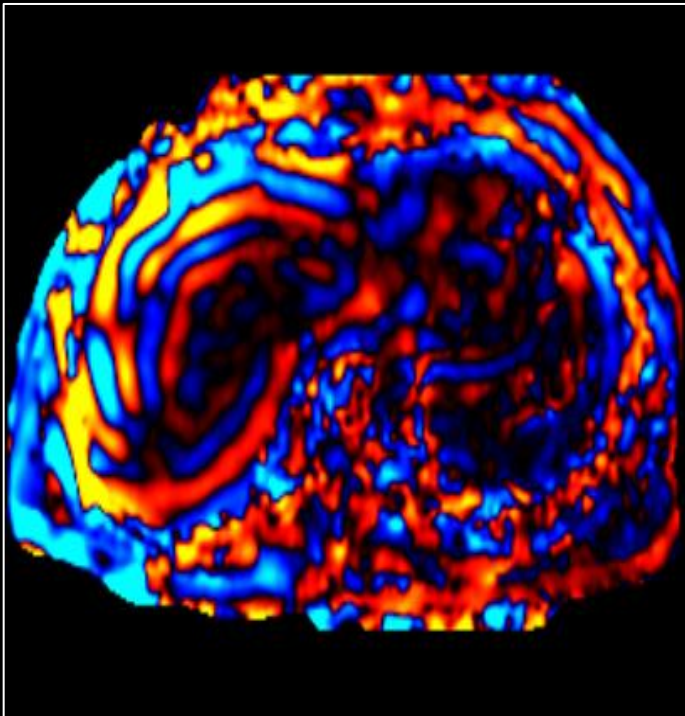
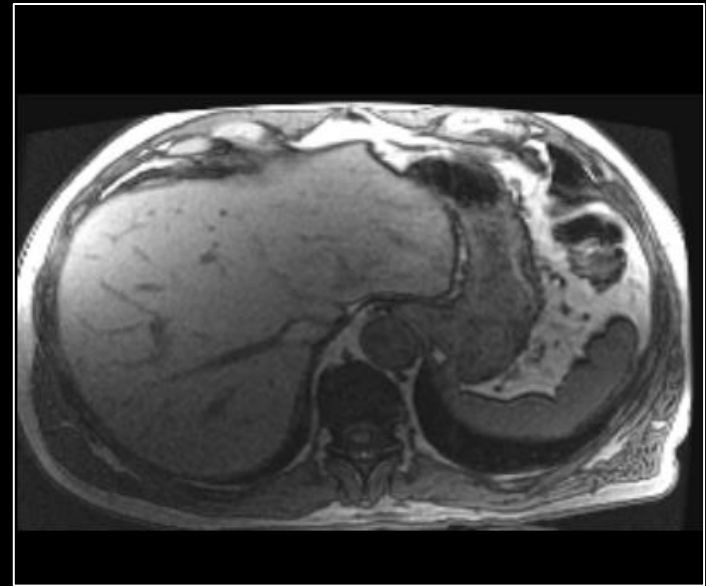
**Wave Images** → **Elastogram**



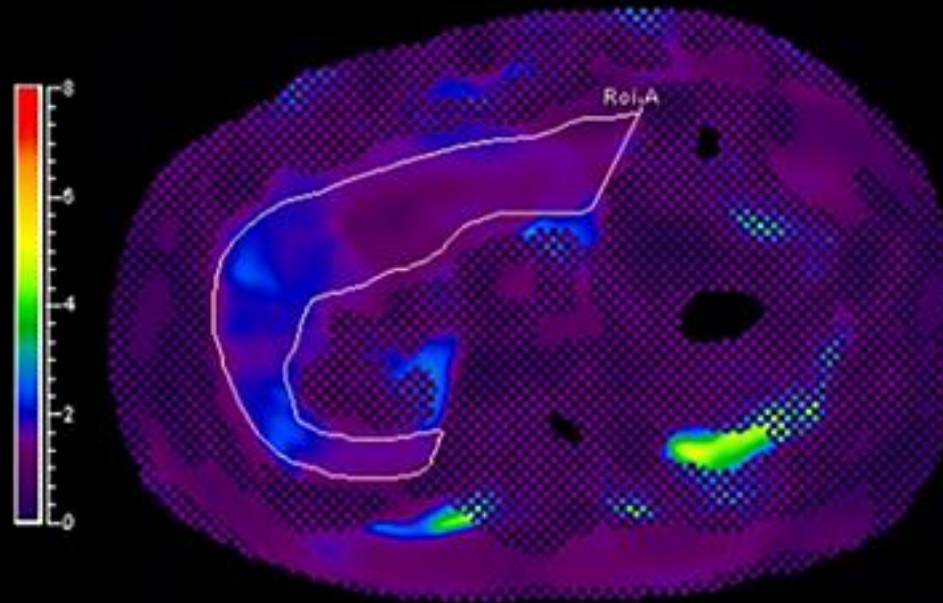
# Conventional MRI exam of the Abdomen

~45 min

MR Elastography adds  
~5-10 min but does not  
require contrast  
(15 second scan)



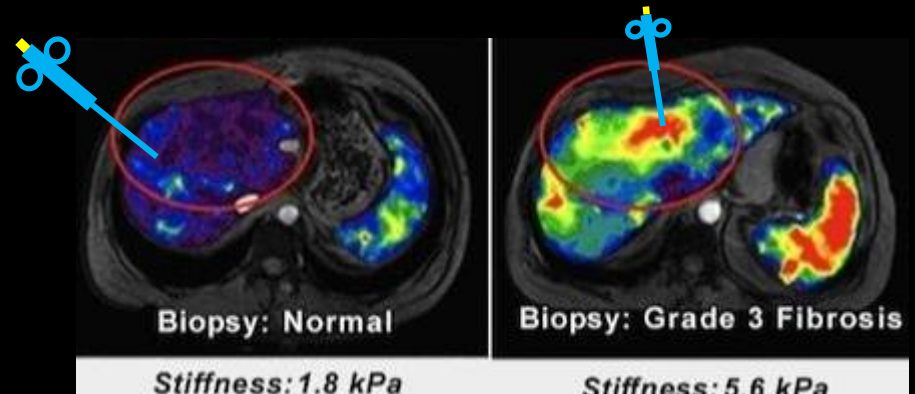
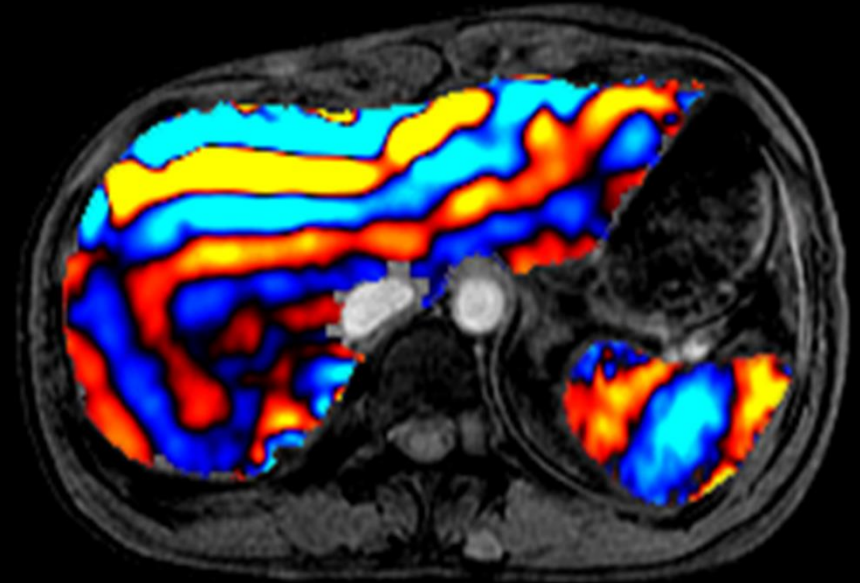
# Confidence Map



- A confidence algorithm is used to generate a map (checkerboard pattern) to indicate regions of 95% statistical confidence.

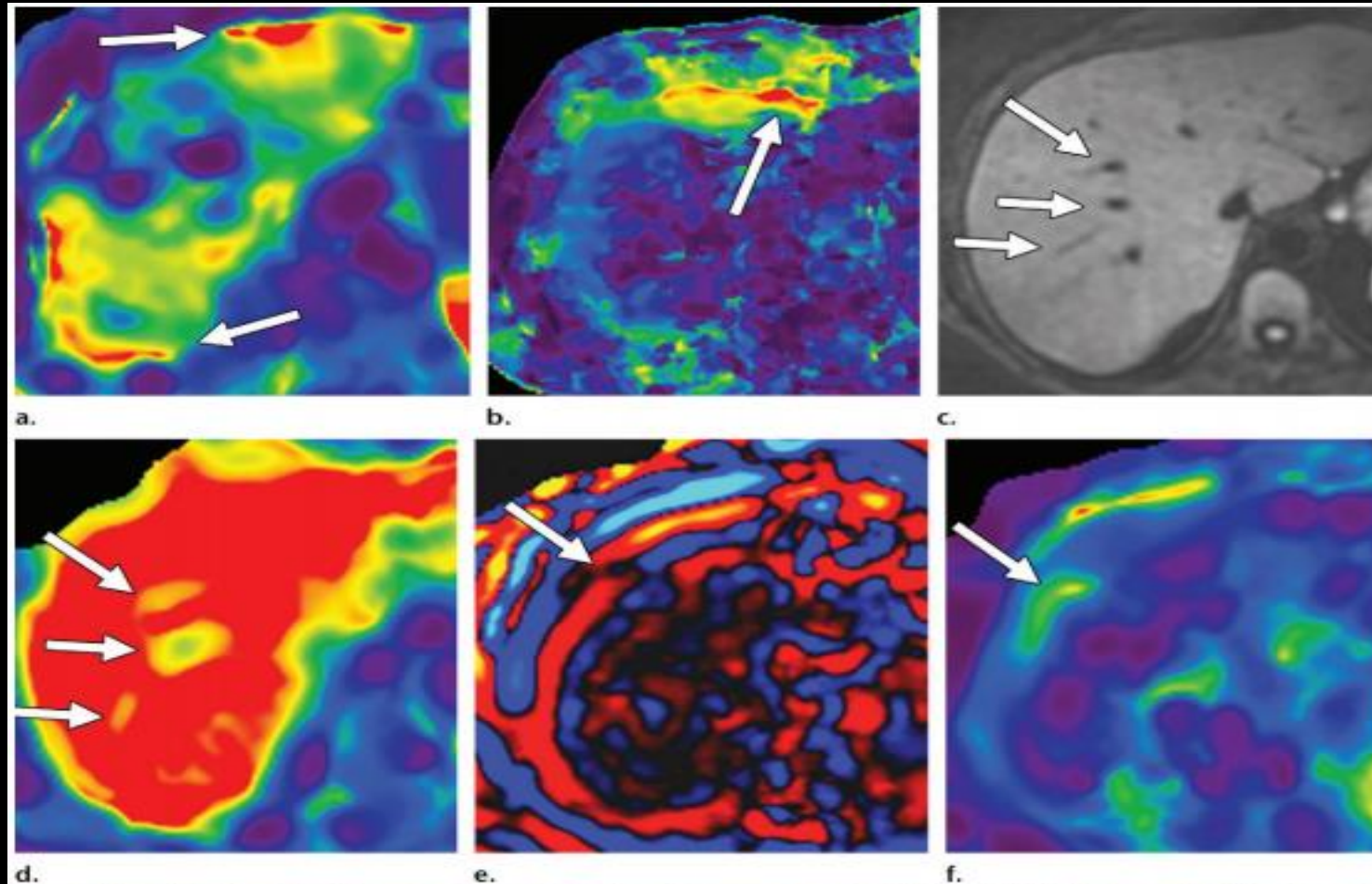
# MRE of the Liver

- Strong correlation between MRE-measured hepatic stiffness, and histologic stage of fibrosis (esp F3/F4)
- Evaluates entire liver
  - Biopsy may miss patchy areas of fibrosis.
- Why is this important?
  - Potential for targeted biopsy and increased diagnostic yield.





# MR Elastography Artifacts



**Figure 14.** Artifacts that should be excluded from MR elastographic measurements of stiffness. (a) MR elastogram: For ROI placement, typically about 1 cm, or one-half of a wavelength, is excluded around the edge of the liver, including fissures and fossa, to account for partial volume effects (arrows), which may result in an artificially high stiffness calculation. (b) MR elastogram shows an artifactual "hot spot" (arrow) that is often found directly under the passive driver. (c, d) Axial diffusion-weighted MR image (c) and MR elastogram (d) show that large (>3-mm) vessels (arrows) do not reflect parenchymal stiffness. (e, f) A wave image (e) and MR elastogram (f) show that regions of wave interference (arrow) can be constructive or destructive, resulting in variable effects on the liver stiffness.

# MR Elastography

## Strengths

- High diagnostic **accuracy** and **reproducibility** for fibrosis
- Works well with ↑ body habitus, ascites
- Assesses large volume of liver
- Provides anatomic information – biopsy guidance

## Limitations

- Pitfall with iron deposition disorders
  - Poor signal generation
- Requires post-processing & offline analysis
- Limited availability
- Requires consistent breath-holding for accurate results

# MR Elastography Template

## Technique

- Patient NPO 4-6 hours
- Axial T2 HASTE, Axial in and out of phase, Coronal T2 Haste.
- *"MR elastography was performed using standard technique, with post processing done separately on the Siemens workstation."*

# MR Findings to Include in Report

- Liver background signal:
- Liver size:
- Liver contour:
- Ascites:
- Varices:
- Assessment of liver stiffness:
  - Overall stiffness measurements range from (    ) kpa.
  - Average background liver stiffness is (    ) kpa.
  - These measurements correspond to an F-score of (    ).

# Meta-Analysis

Singh et. Al., Clinical Gastroenterology and Hepatology 2015;13:440–451

## 12 retrospective studies between 2003-2013

- Used liver biopsy as reference standard

## 697 patients with chronic liver disease

- Mean age,  $55 \pm 13$  years
- 59.4% male
- 47% with Hepatitis C
- 92% with <1 year interval between MRE and Biopsy

## AUROC (95% CI), MRE cut-off value

- $\geq$ Stage 1 – 0.84 (0.76-0.92), 3.45 kPa – “Good”
- $\geq$ Stage 2 – 0.88 (0.84-0.91), 3.66 kPa – “Good”
- $\geq$ Stage 3 – 0.93 (0.90-0.95), 4.11 kPa – “Excellent”
- $\geq$ Stage 4 – 0.92 (0.90-0.94), 4.71 kPa – “Excellent”
- NAFLD – Any/significant/advanced fibrosis/cirrhosis: 0.89/0.90/0.94/0.90

## MRE failure rate - 4.3%

# Quantitative Elastography Methods in Liver Disease: Current Evidence and Future Directions<sup>1</sup>

**Table 4**

**Reported Diagnostic Performance of MR Elastography for Liver Fibrosis Staging in Mixed-Etiology Cohorts, Chronic HBV or HCV, and NAFLD**

First Author and Year	Region	Manufacturer and Sequence	Field Strength	Design	Etiology	No. of Patients	Success (%)	Stage F2–F4				Stage F3–F4				Stage F4			
								AUC	Cutoff (kPa)	Sens	Spec	AUC	Cutoff (kPa)	Sens	Spec	AUC	Cutoff (kPa)	Sens	Spec
Yin 2007 (84)	United States	GE (2D GRE)	1.5 T	P	Mixed	85	98	0.92	4.89	0.86	0.85	0.92	6.47	0.78	0.96	0.92	6.47	0.89	0.90
Huwart 2008 (85)	Europe	Philips (3D SE)	1.5 T	P	Mixed	141	94*	0.99	2.49	1	0.91	0.96	3.13	0.91	0.97	0.998	4.13	1	0.96
Asbach 2010 (38)	Europe	Siemens (2D SE EPI)	1.5 T	P	Mixed	74	99	0.92	3.18	0.77	0.97	0.97	3.32	0.97	0.87	0.99	4.21	1	0.91
Wang 2011 (86)	United States	Siemens (2D GRE)	1.5 T	P	Mixed	78	97	0.98	5.37	0.91	0.97	0.99	5.97	0.92	0.95	0.95	5.97	0.95	0.87
Dyvorne 2016 (87)	United States	GE/S (2D GRE)	1.5 T/3 T	P	Mixed	42	90	0.78	3.9	0.6	1	0.94	4.07	0.9	0.92	—	—	—	—
Chen 2016 (88)	United States	GE (2D GRE)	1.5 T	P	Mixed/obese	110	96	0.93	3.5	0.82	0.9	0.92	3.60	0.84	0.83	0.95	4.52	0.82	0.91
Ichikawa 2012 (89)	Asia	GE (2D GRE)	1.5 T	R	HCV	119	96	0.99	3.2	0.89	1	0.97	4.00	0.87	1	0.97	4.6	1	0.86
Shi 2014 (90)	Asia	GE (2D GRE)	3 T	P	HBV	132	91	0.99	4.07	0.95	0.95	1	5.45	1	1	0.998	6.87	1	0.99
Chang 2016 (91)	Asia	GE (2D GRE)	1.5 T	R	HBV	539	91†	0.97	2.57	0.89	0.96	0.94	2.78	0.93	0.85	0.92	3.67	0.8	0.93
Shi 2016 (92)	Asia	GE (3D SE EPI)	3 T	P	HBV/HCV	179	98	0.97	2.79	0.95	0.91	0.99	3.28	1	0.91	0.98	3.57	0.97	0.9
Loomba 2014 (93)	United States	GE (2D GRE)	3 T	P	NAFLD	117	100	0.86	3.58	0.66	0.92	0.92	3.64	0.86	0.91	0.89	4.67	0.8	0.94
Cui 2016 (81)	United States	GE (2D GRE)	3 T	P	NAFLD	126	99	0.89	3.62	0.67	0.96	0.93	3.62	0.91	0.95	0.88	4.15	0.59	0.78
Imajo 2016 (94)	Asia	GE (2D GRE)	3 T	P	NAFLD	142	100	0.89	3.4	0.87	0.85	0.89	4.80	0.75	0.87	0.97	6.7	0.91	0.95

Note.—AUC = area under the receiver operating characteristic curve, GE = General Electric, GRE = gradient recalled echo, HBV = hepatitis B virus, HCV = hepatitis C virus, NAFLD = nonalcoholic fatty liver disease, P = prospective, R = retrospective, SE = spin echo, Sens = sensitivity, Spec = specificity, 3D = three-dimensional, 2D = two-dimensional.

\* Reported for 96.

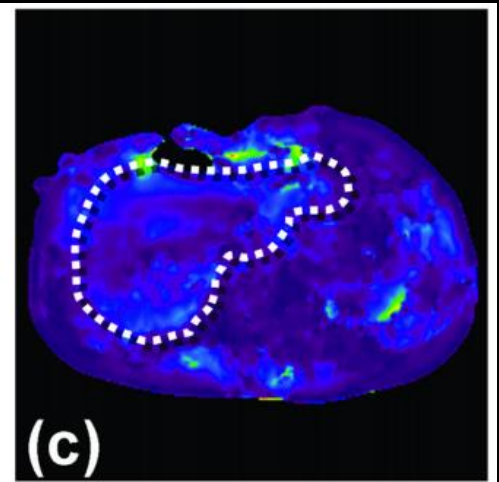
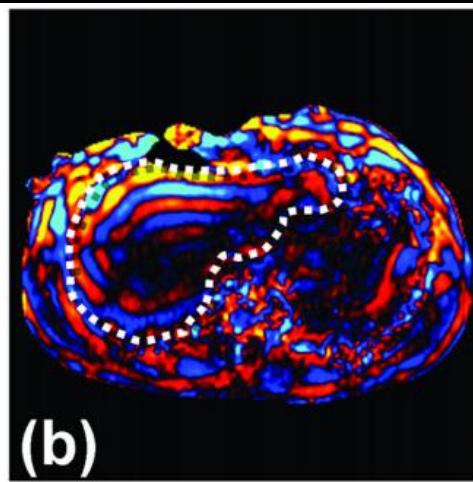
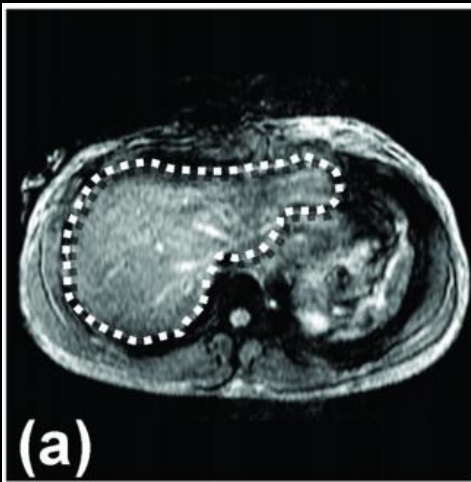
† Reported for 270.

MR elastography has continued to demonstrate a strong correlation between MRE stiffness over a larger area and histological stage of hepatic fibrosis.


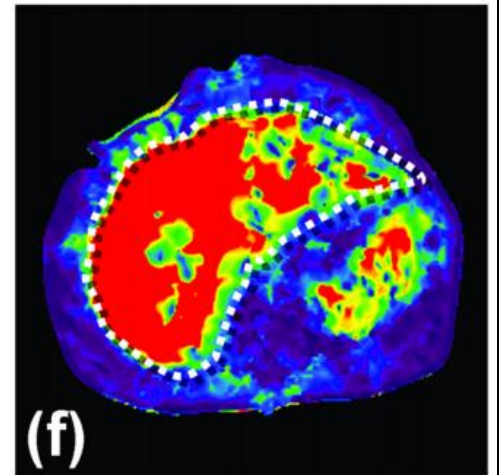
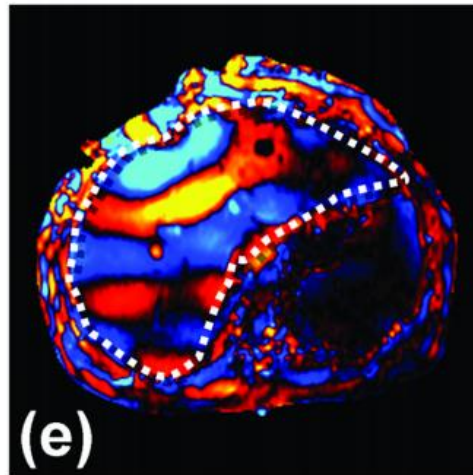
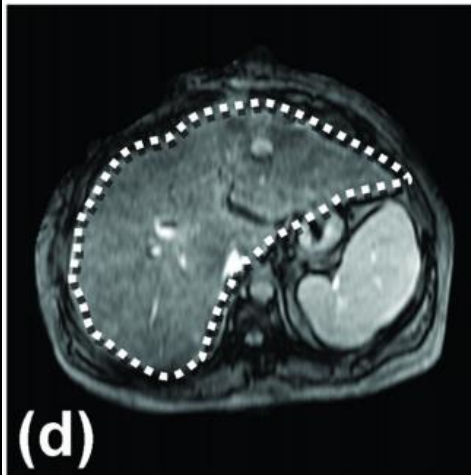
# Case Review



**NORMAL**

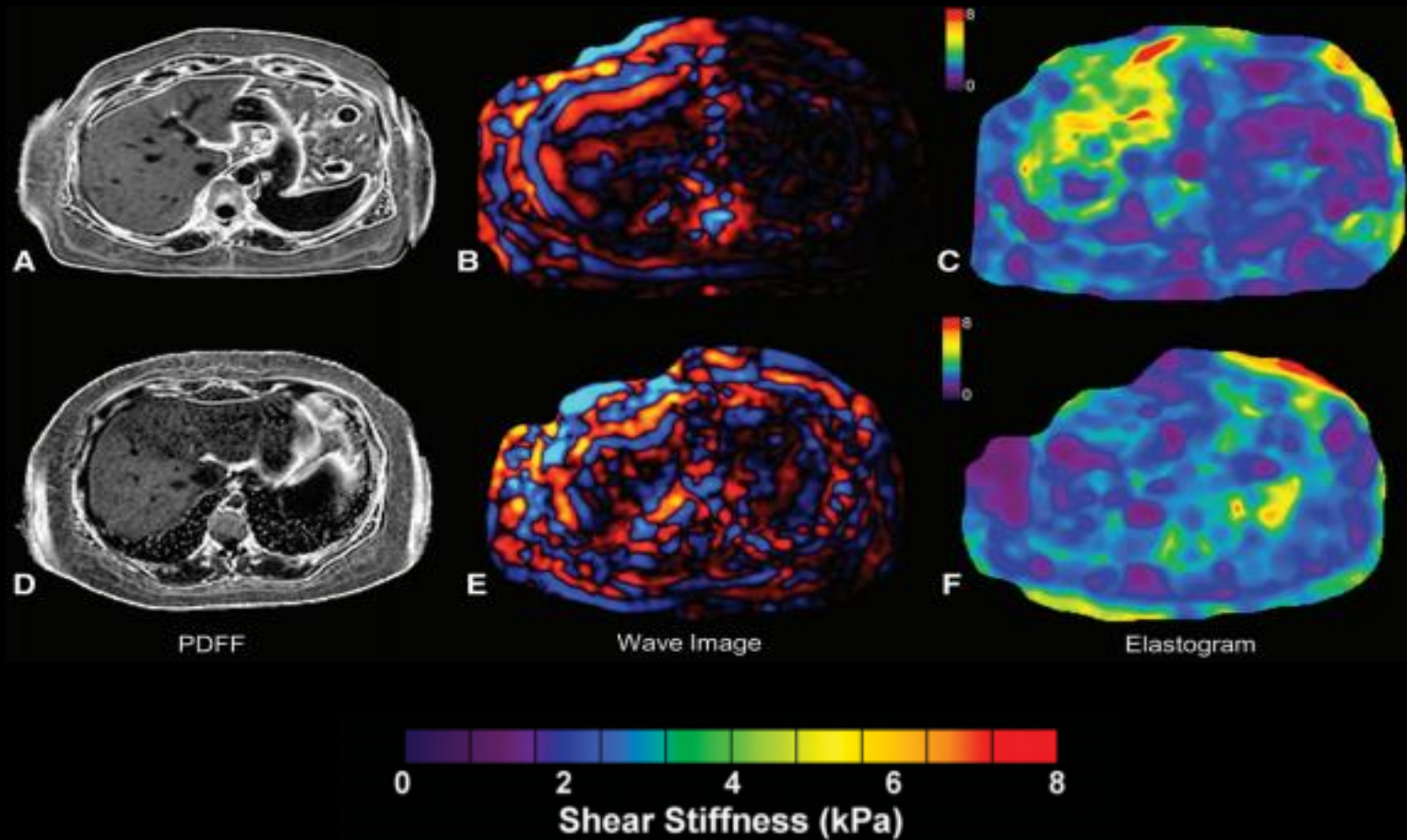


**CIRRHOTIC**



Conventional abdominal MR magnitude images of the two patients, showing no significant difference between the two livers. (b,e) Wave images from the MRE acquisition at 60 Hz showing shear waves with a shorter wavelength in the first patient, and a substantially longer wavelength in the second patient. (c,f) The corresponding elastograms indicating that the two livers were normal (1.7 kPa) and cirrhotic (18.83 kPa), respectively. *Clin Anat.* 2010 July ; 23(5): 497–511. doi:10.1002/ca.21006.

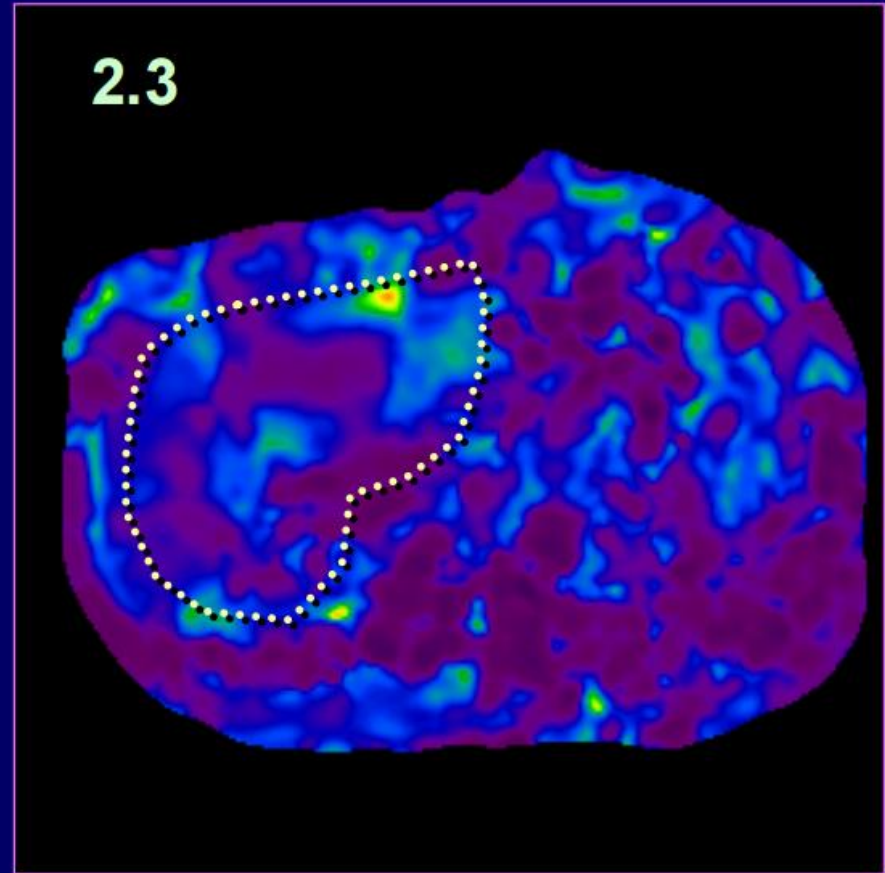
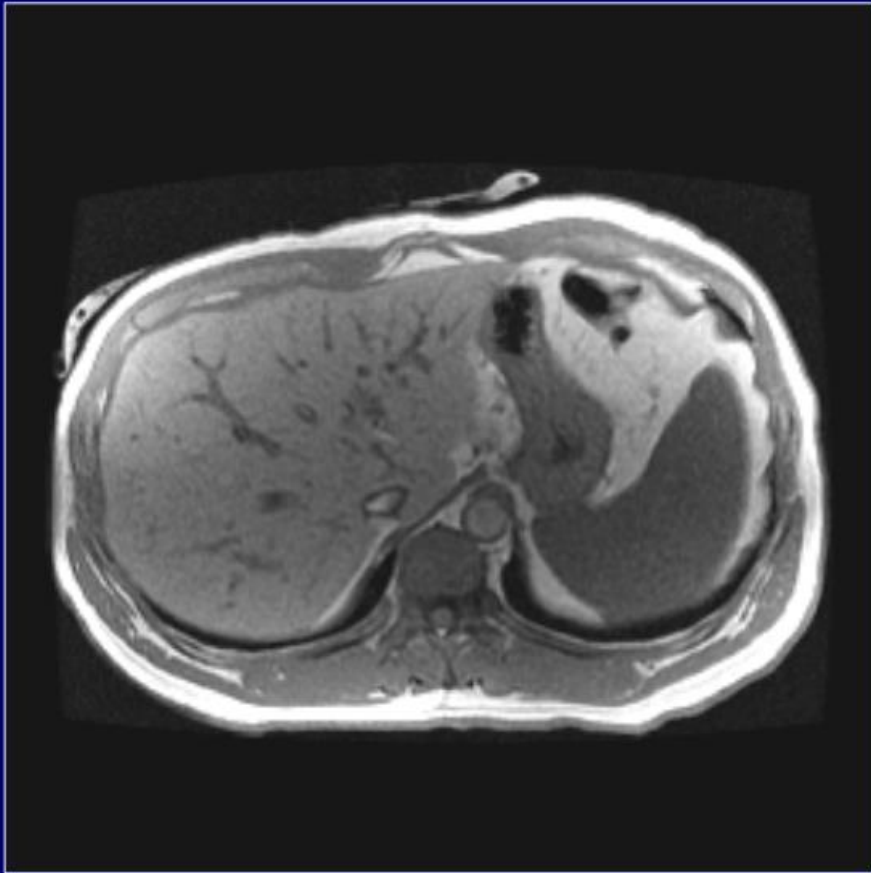




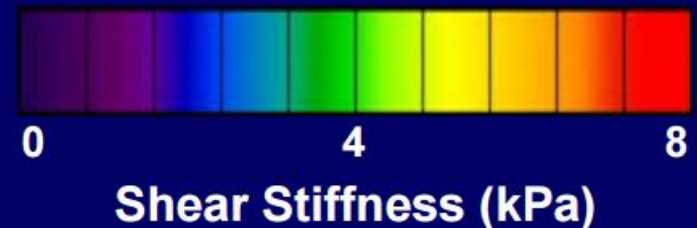Top row: 43 yo female with nonalcoholic steatohepatitis and advanced fibrosis (stage F3) at liver biopsy.

Bottom row: 29 yo female with nonalcoholic fatty liver disease with no fibrosis (stage F0) at liver biopsy.

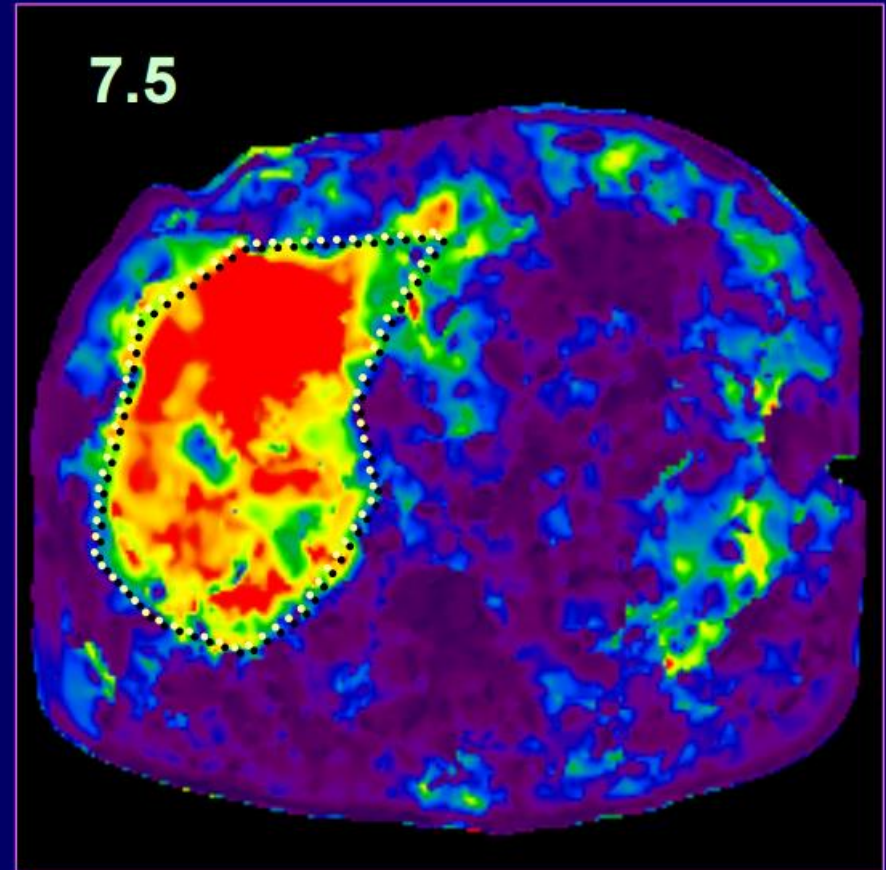
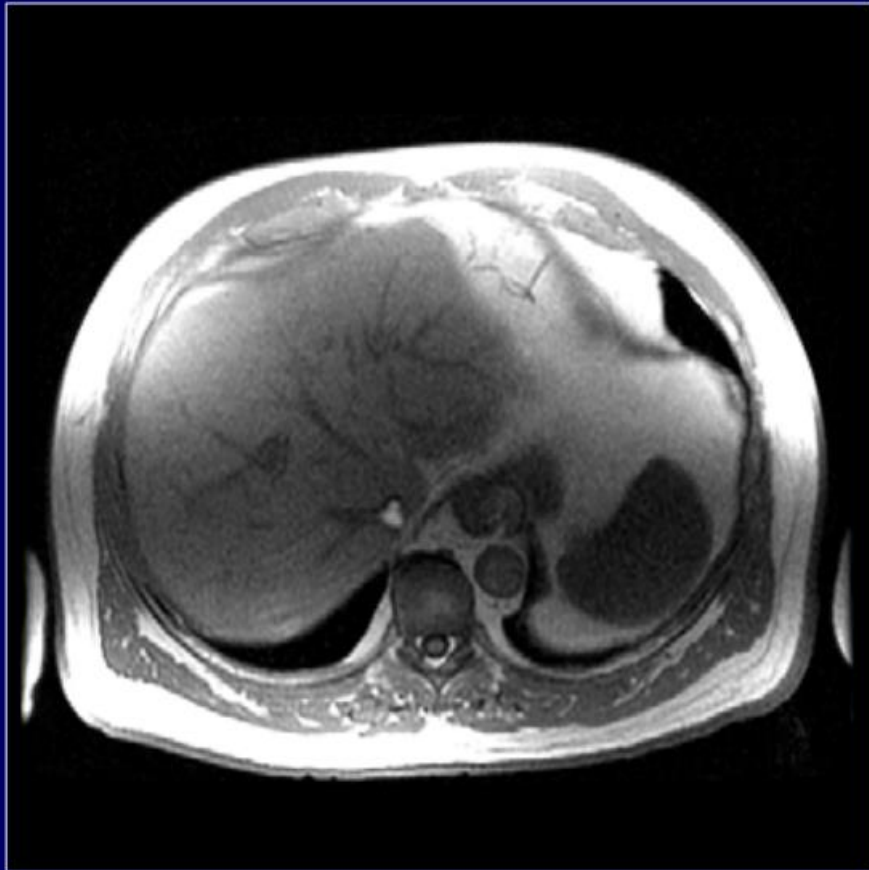# 41 yo Patient – Fatty Liver Disease



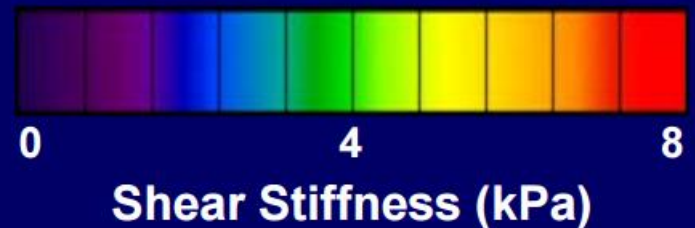- **Biopsy : No fibrosis**



# 69 yo Patient - Fatty Liver Disease

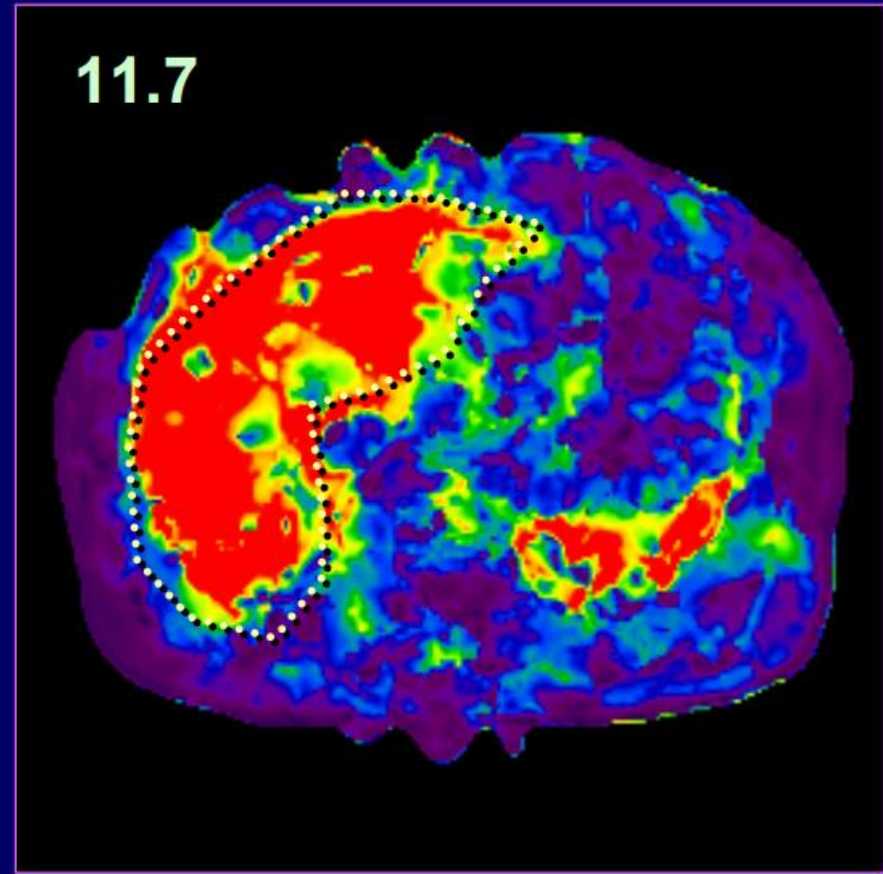
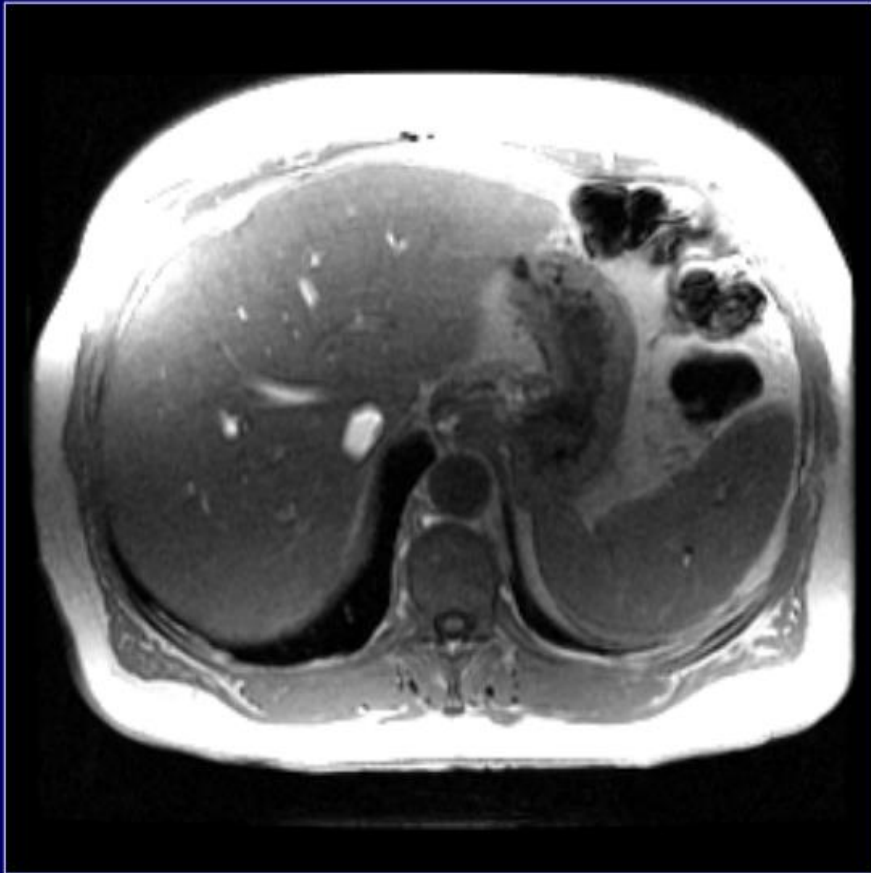

- **Biopsy : Stg. 3 fibrosis**

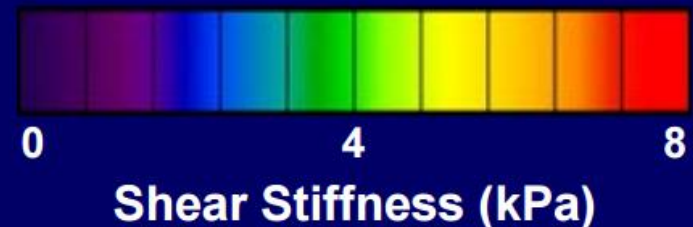



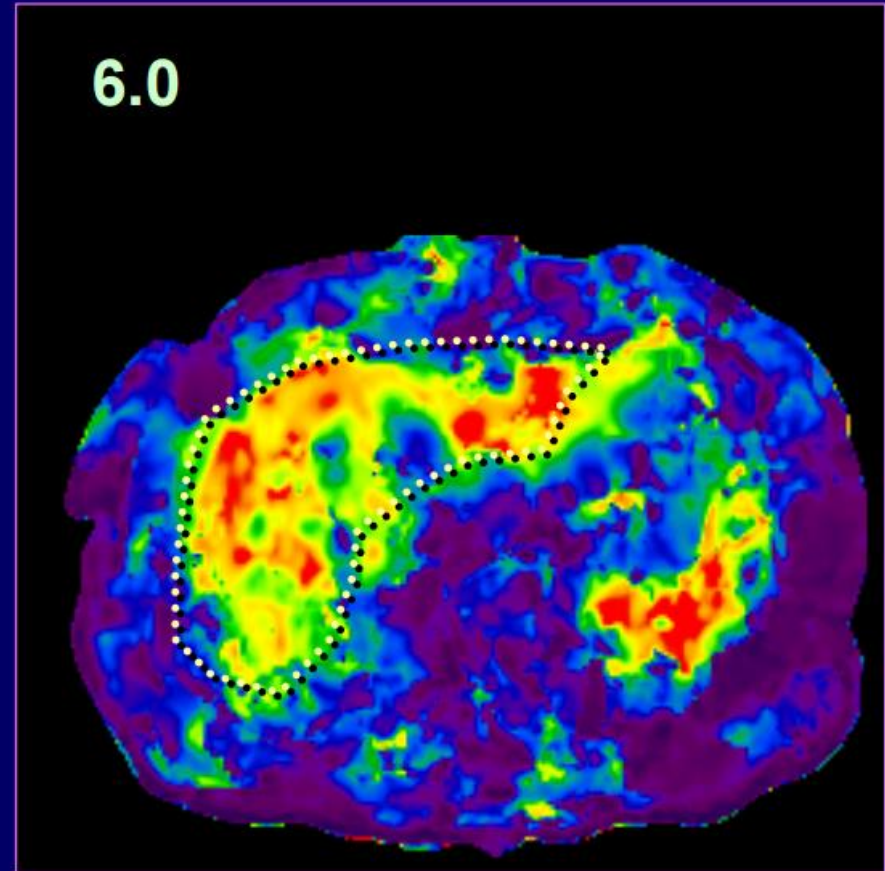
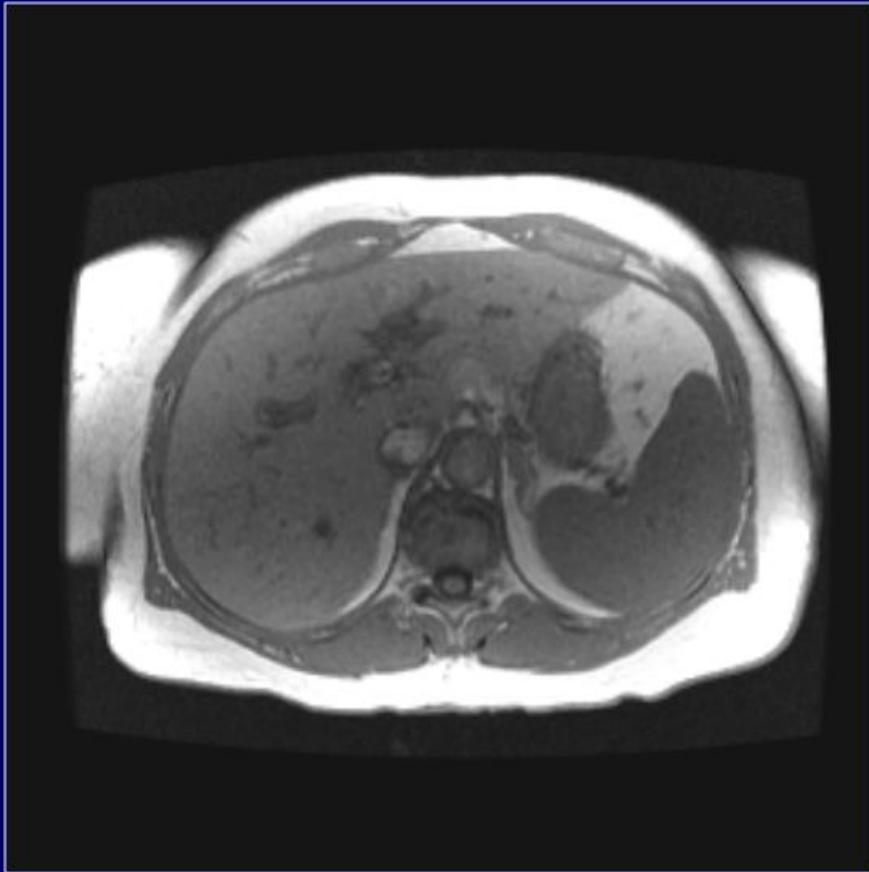
# 55 yo Patient – Chronic Hepatitis C



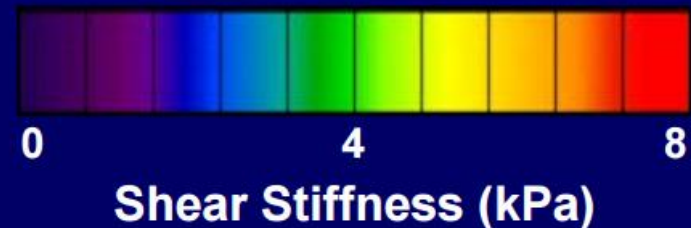- **Biopsy: Not performed**



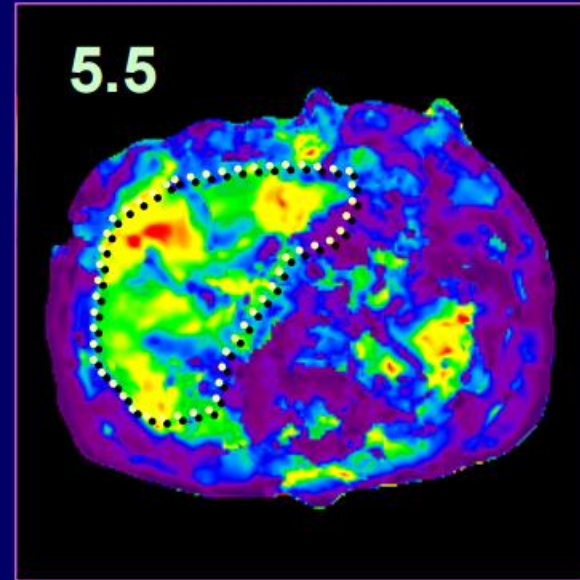
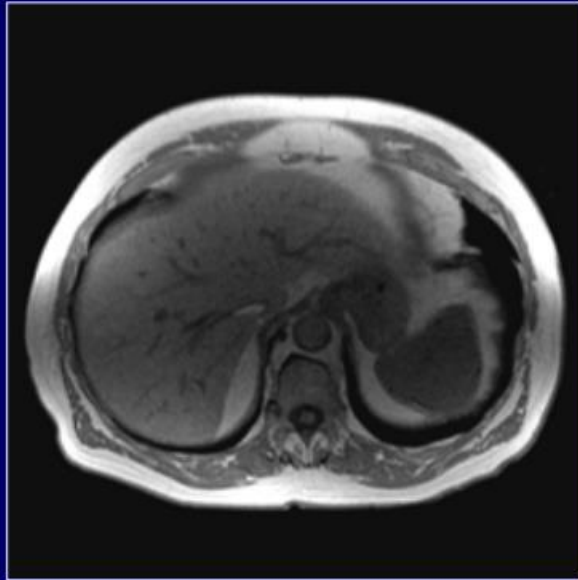
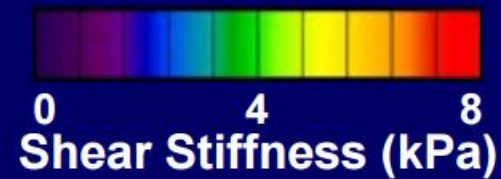# 59 yo Patient – Alcohol



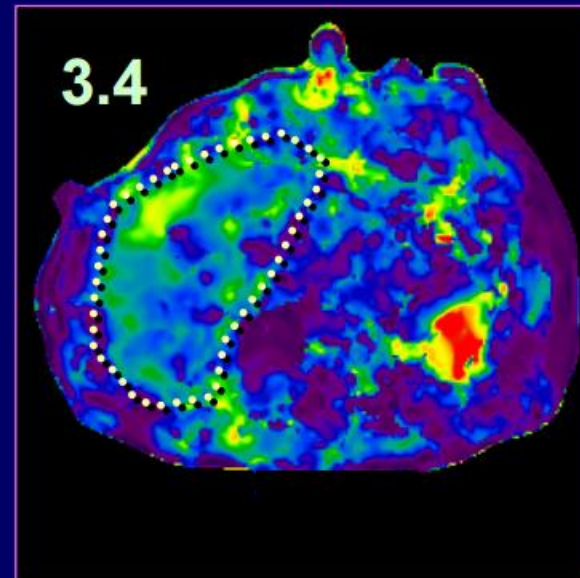
- Biopsy : Stg. 4 fibrosis



# 76 yo Patient - Alcohol



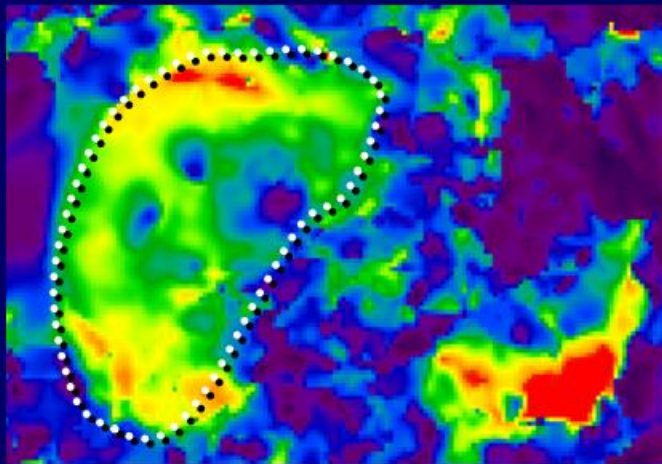
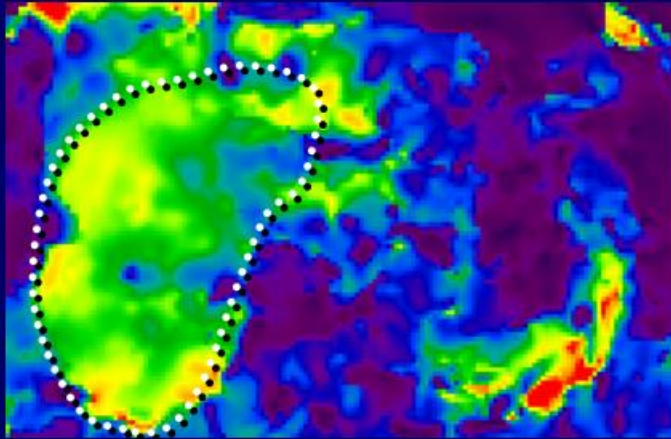
**Abstinent  
9 months later**





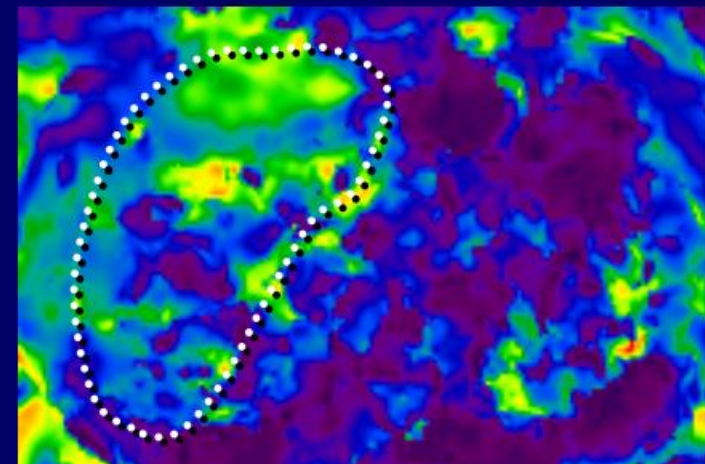
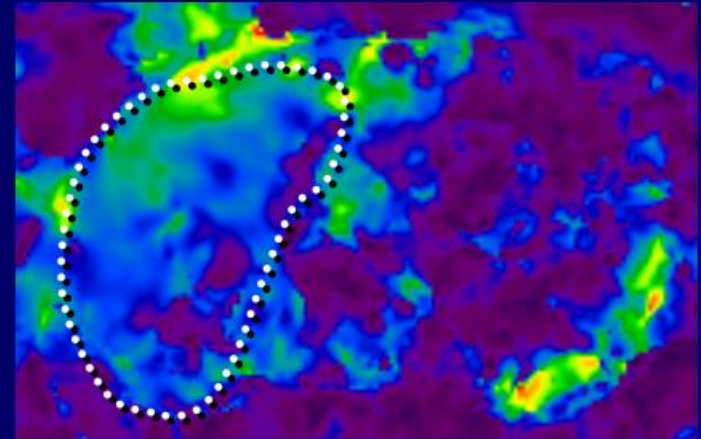
# 47 yo female with Autoimmune Hepatitis

8/14/07



**Mean Liver Stiffness: 4.0 kPa**  
**Liver Biopsy Score = F2**

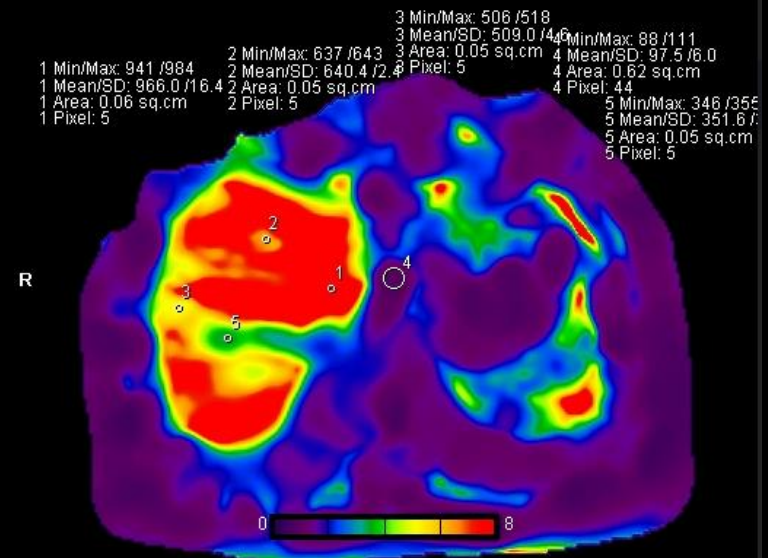
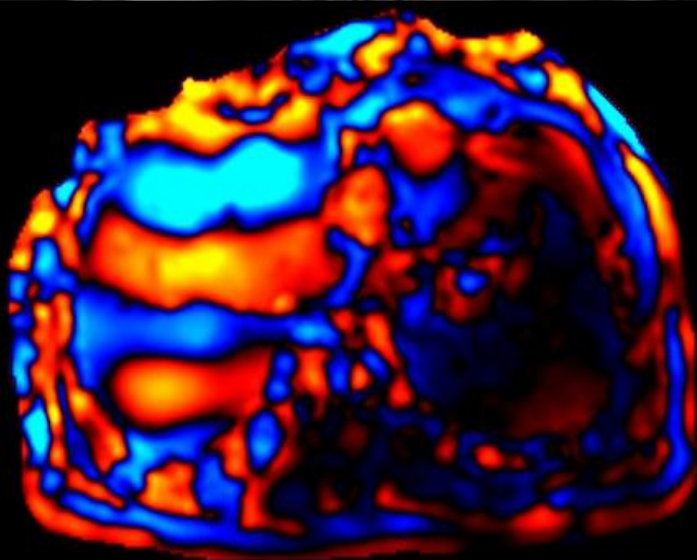
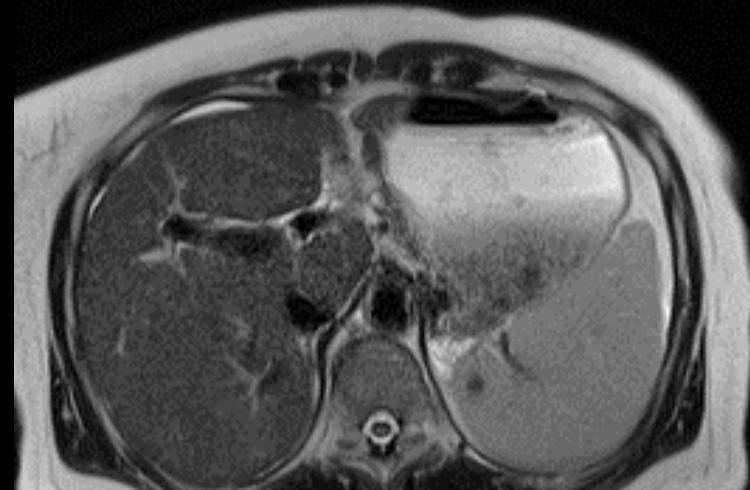
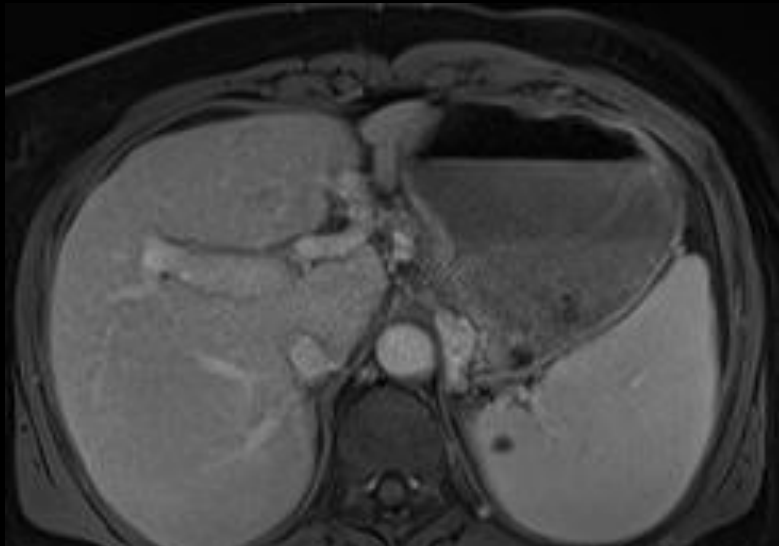
6/18/09



**Mean Liver Stiffness: 2.9 kPa**  
**Liver Biopsy Score = F0**

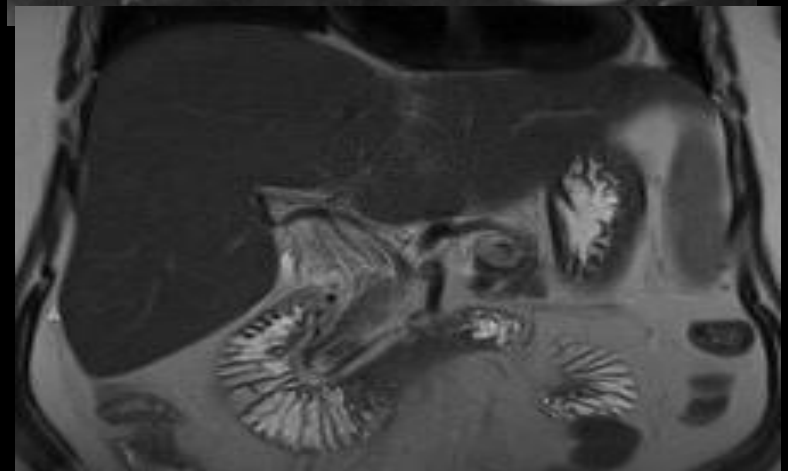
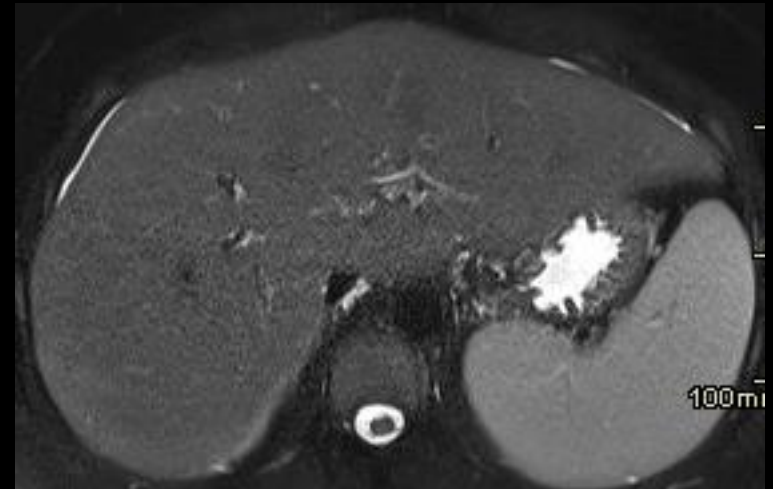
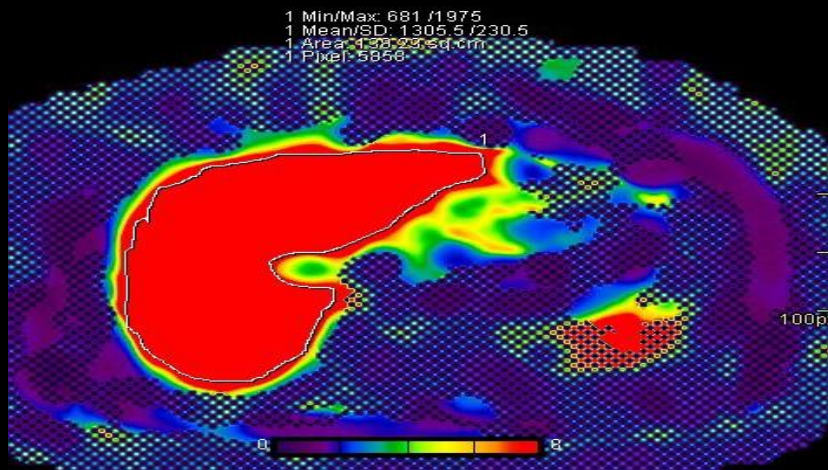

# 46 F, suspected cirrhosis, ?etiology

Stiffness 9.6 – F4





**45 year old female with previous elevated liver enzymes NYD.  
Abdominal US demonstrated severe fatty infiltration and  
hepatomegaly.**



**Stage F4 Fibrosis**

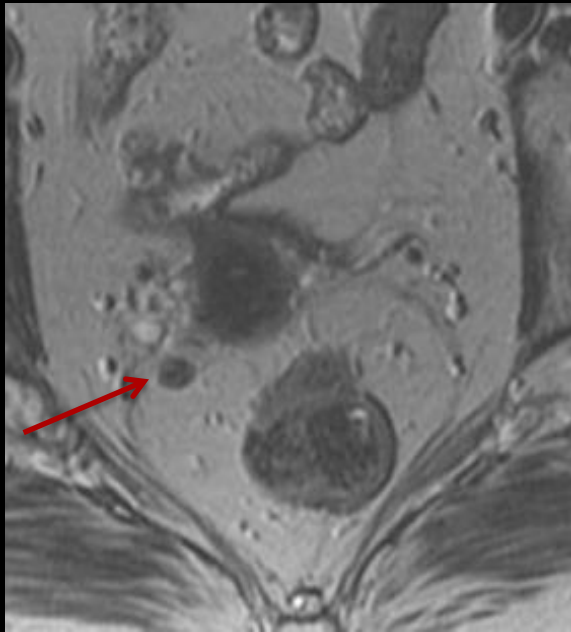
# Teaching Points

- To achieve a quality examination, adequate technical training, adherence to protocol, and awareness of artifacts are key.
- MR Elastography can help to target biopsy or even identify cases where biopsy may not even be necessary (ie. Cirrhosis = stage F<sub>4</sub>, NAFLD = no fibrosis).
- MRE can obviate the need for biopsy follow-up.
- Limitation of MR Elastography – excellent at detecting fibrosis; however, does not provide a pathologic diagnosis of the *cause* of fibrosis.

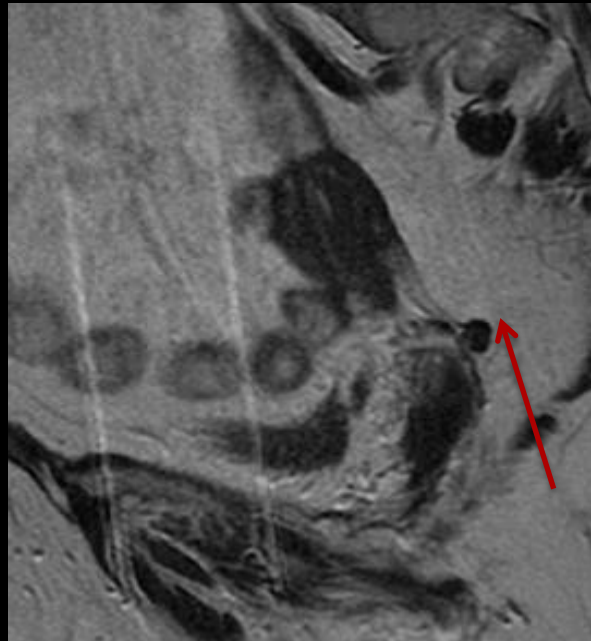
# Quality Assurance Cases

# 74 year old female with high rectal cancer

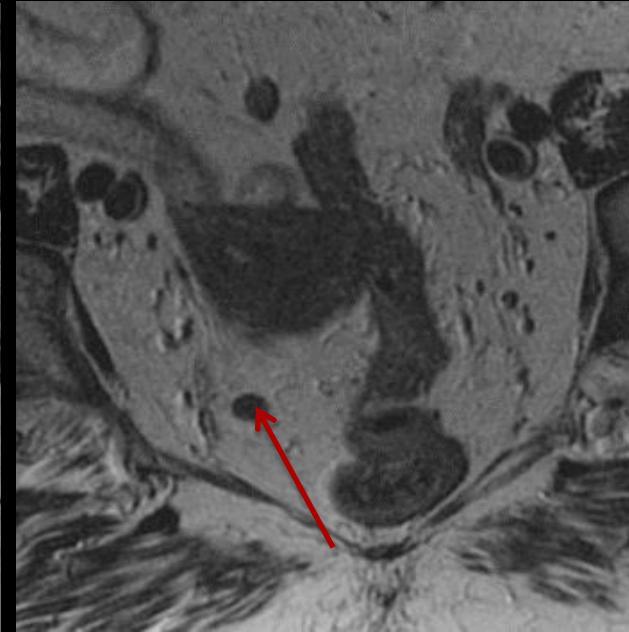
## How would you stage this lesion?



Ax T<sub>2</sub>

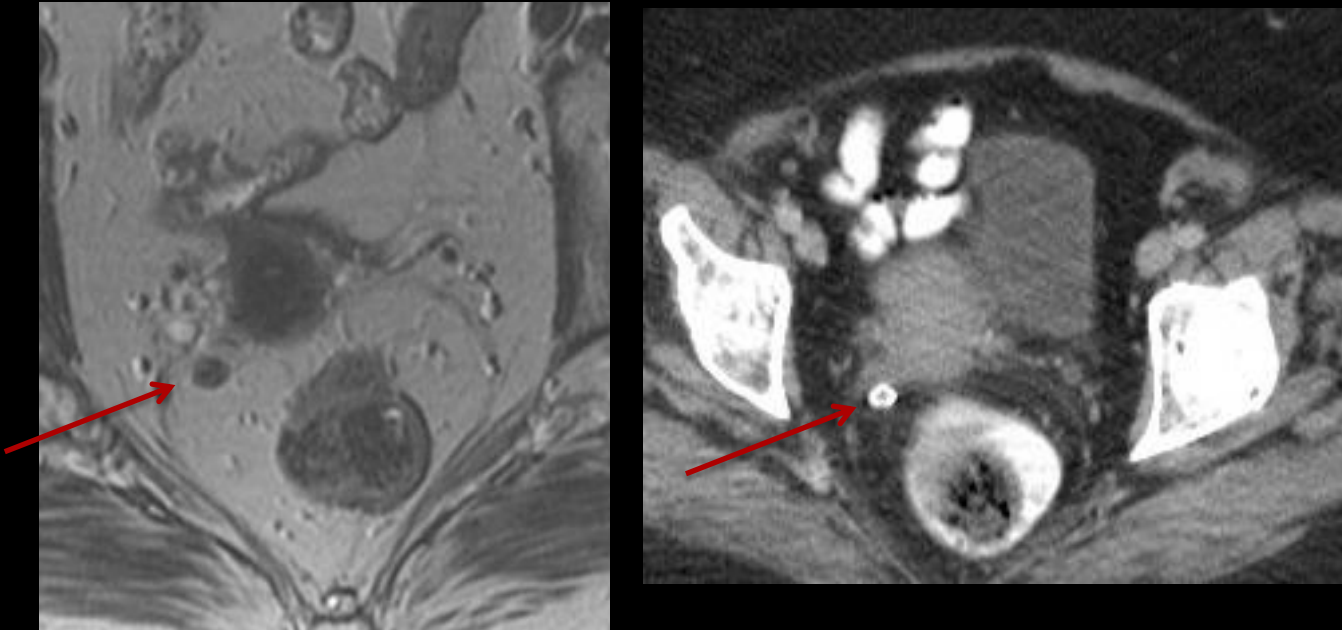


Sag T<sub>2</sub>



Ax oblique T<sub>2</sub>

# Tumor Stage T3b N0



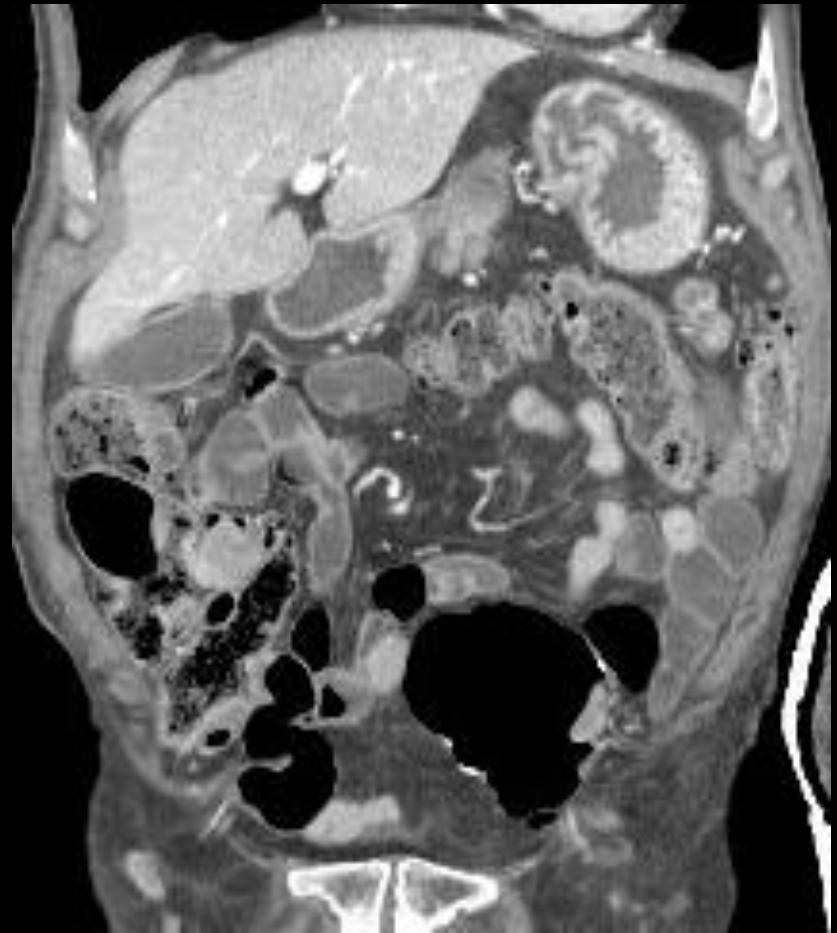
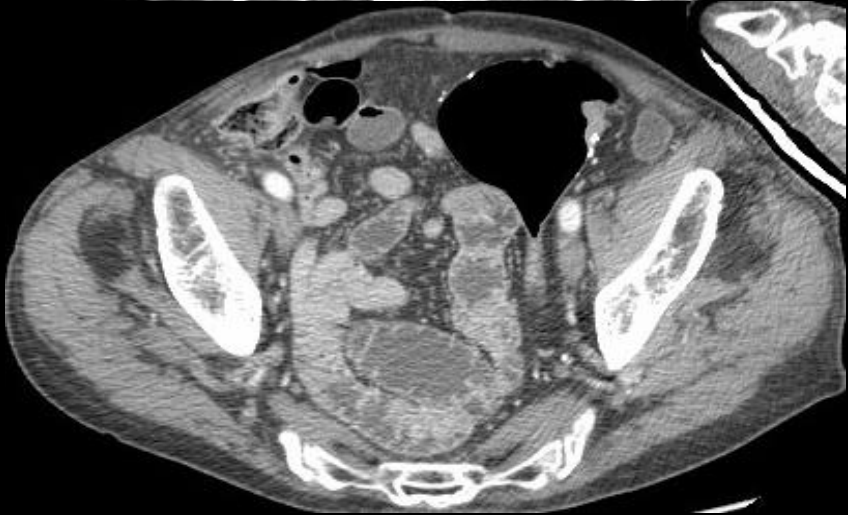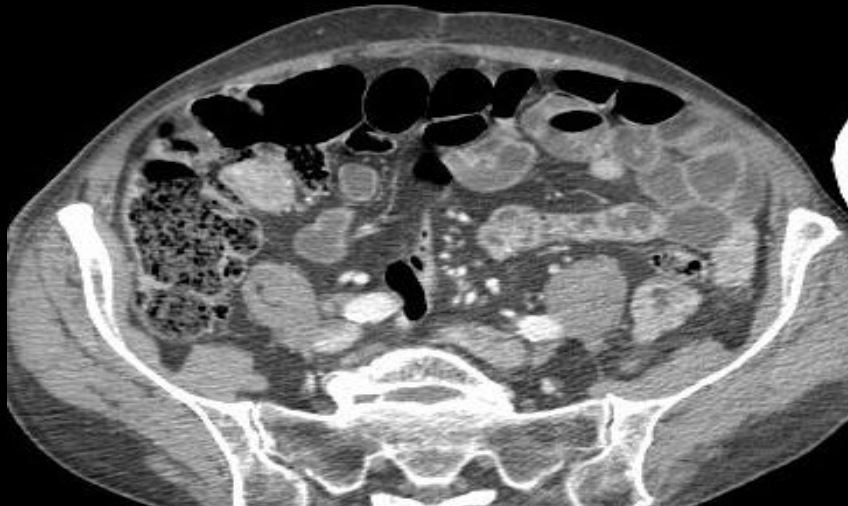
Suspicious lymph node identified within the mesorectal fascia on rectal MR corresponds to a focus of calcification which was evident on previous CT.

# Teaching Point

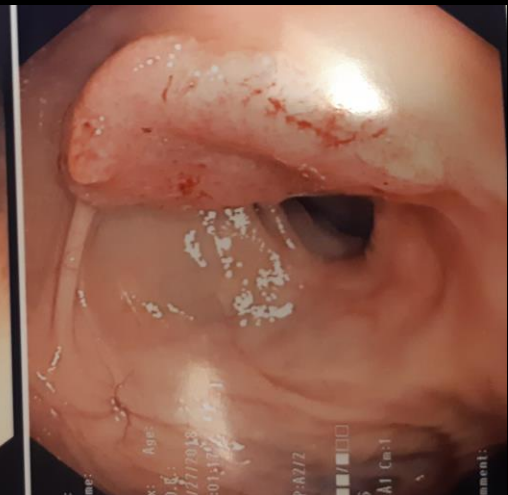
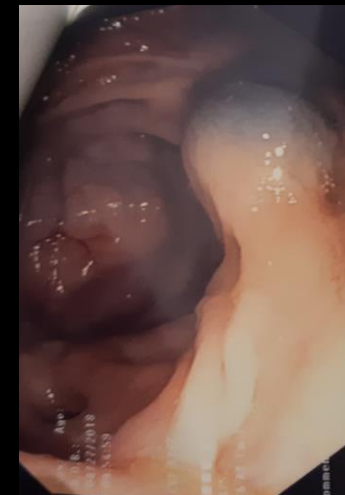
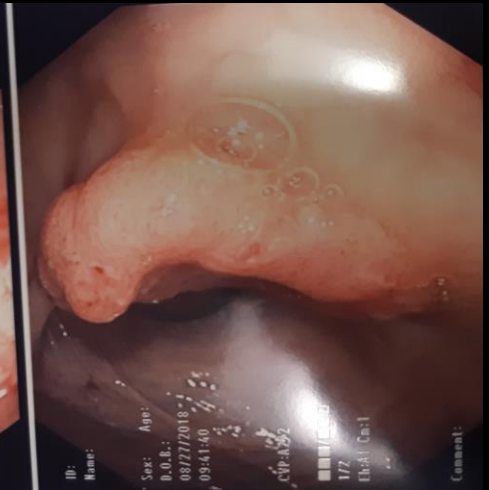
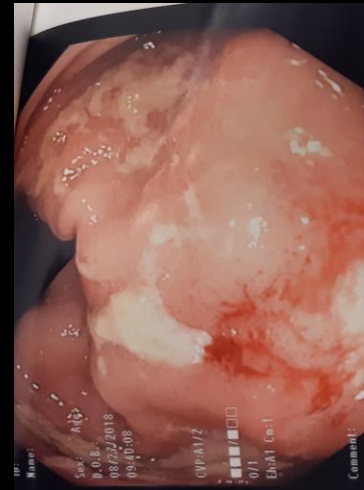
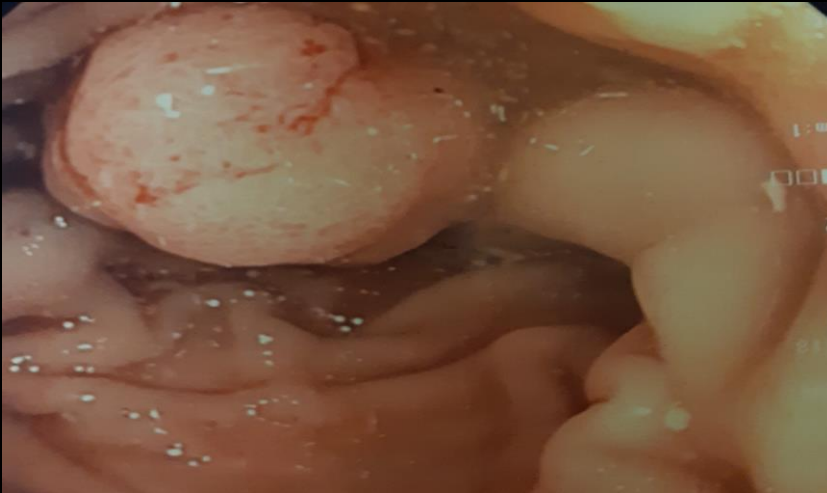
- Always compare to previous!
- Potential for impact on cancer staging and treatment management.
  - Low risk tumor with no lymph nodes = direct to surgery.
  - Intermediate risk tumor with 1-3 suspicious lymph nodes = pre-operative short term radiotherapy.
  - High risk tumor = neoadjuvant chemotherapy and longer course radiation therapy.



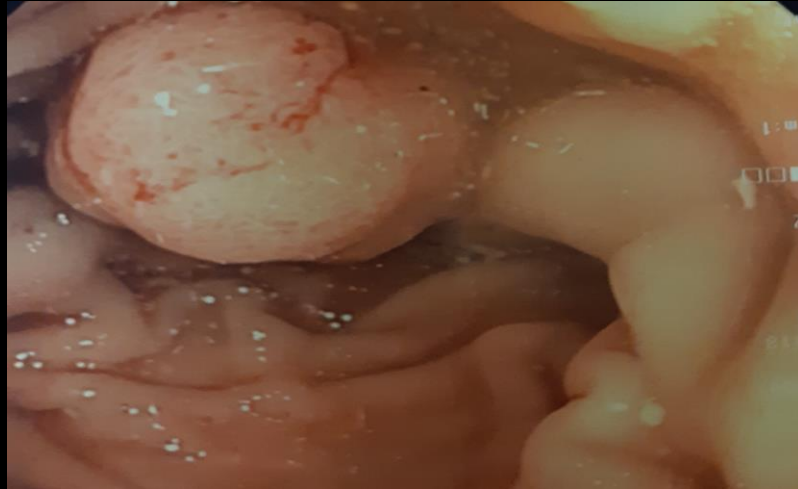
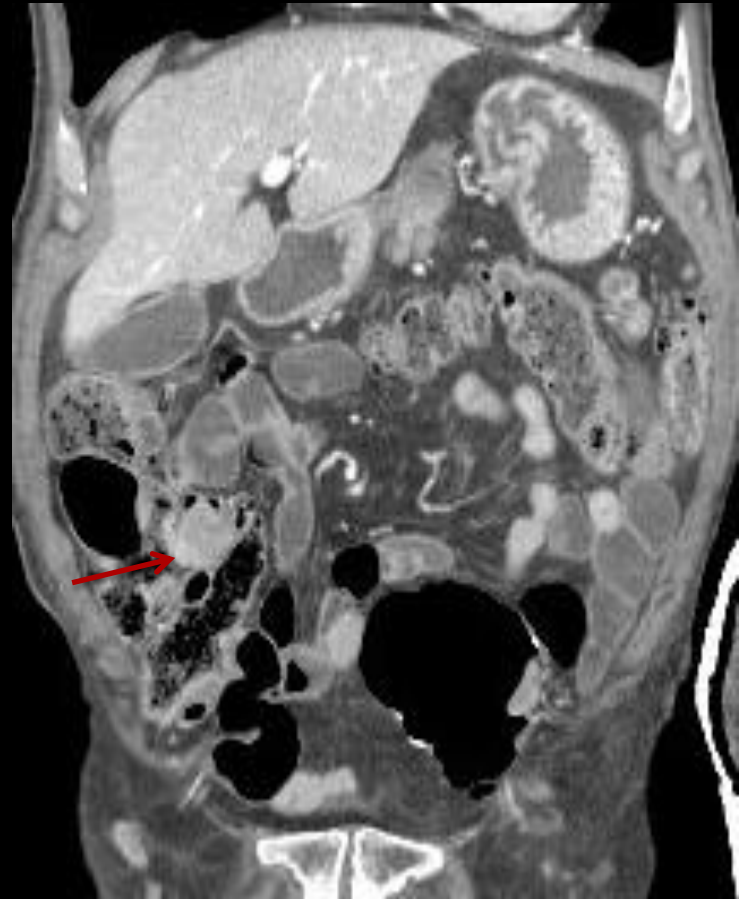
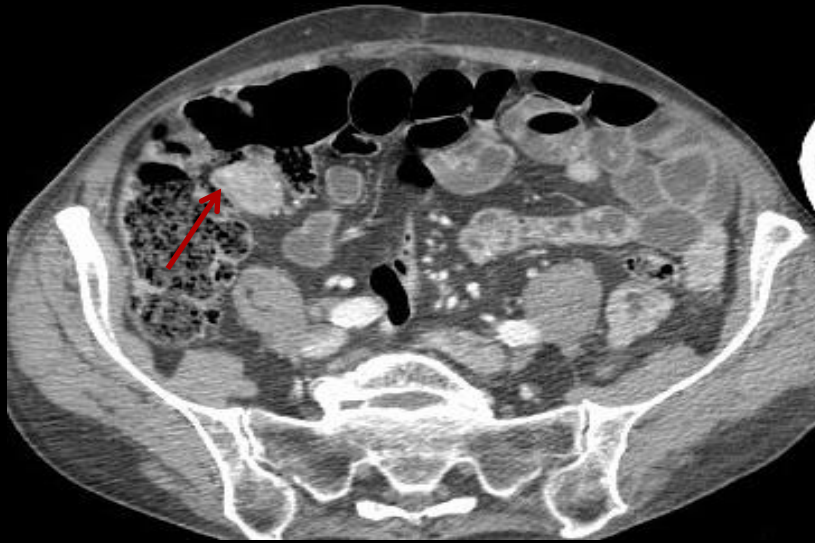**68 year old male trauma patient, pedestrian versus car. Hemoglobin was 93 on admission and decreased to 66 requiring multiple blood transfusions. A follow up CT was requested.**



**Clinical history revealed that the patient had a longstanding history of GI bleeding .  
At endoscopy, three separate colonic lesions were identified.**

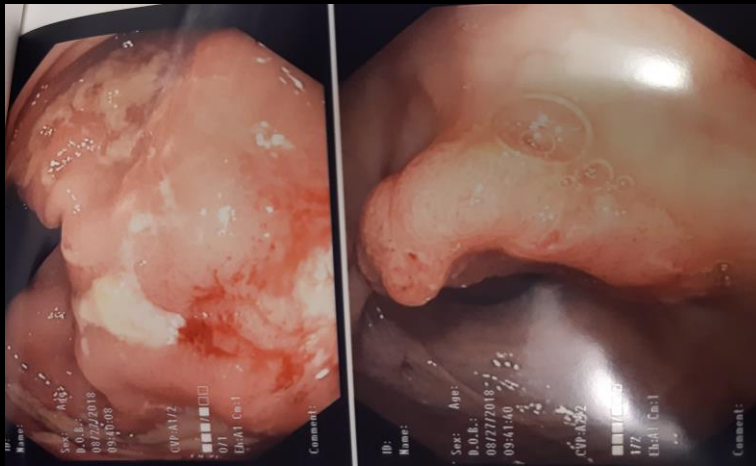
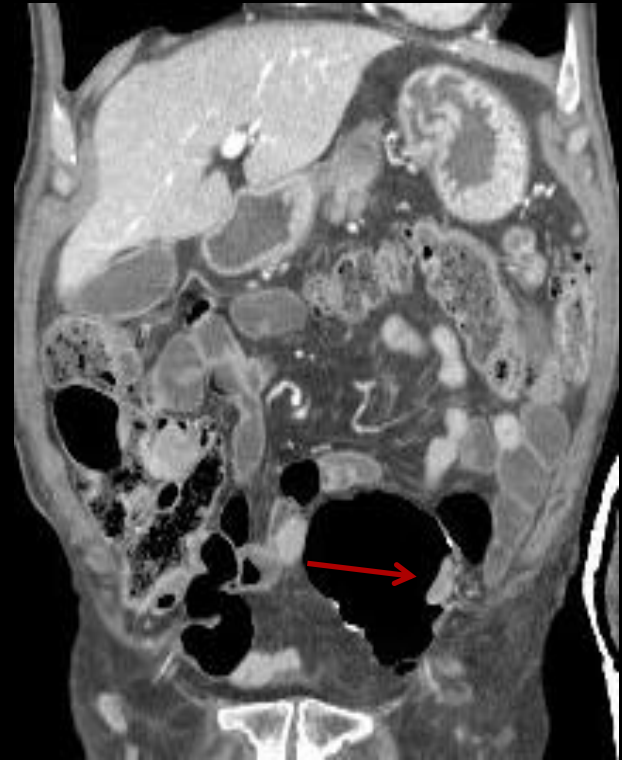
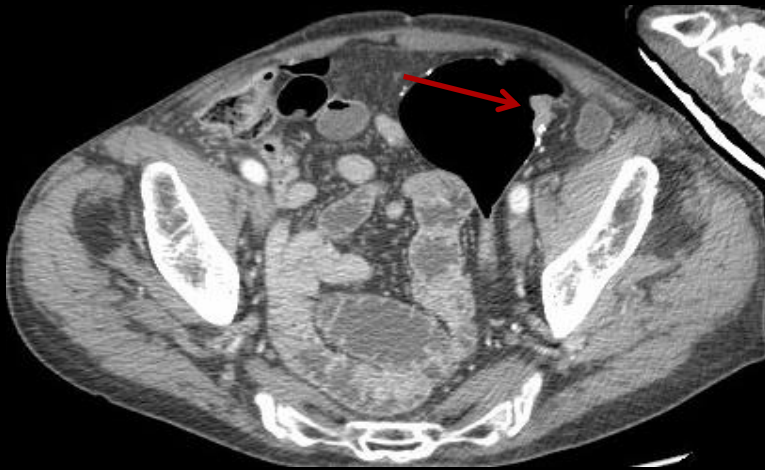





CT demonstrates a large 2.8 x 1.7 cm polypoid mass in the cecum.

Cecum biopsy – villous adenoma. Negative for high grade dysplasia and malignancy.



CT demonstrates a 15 x 22 mm mass with raised rolled edges in the distal sigmoid colon, at the site of surgical clips (patient had a previous bowel resection for perforated viscus).

Rectosigmoid biopsy = moderately differentiated adenocarcinoma.

# Teaching Point

- Despite the clinical context or the history provided, always look for incidental and potentially significant abnormalities.
- Even in bowel that is not prepped with oral/rectal contrast, intraluminal mass lesions can still be identified.

**Thank you!**